Clin Res Cardiol
DOI 10.1007/s00392-009-0101-6

ORIGINAL PAPER

Treatment of small coronary arteries with a paclitaxel-coated balloon catheter

Martin Unverdorben · Franz X. Kleber · Hubertus Heuer · Hans-Reiner Figulla · Christian Vallbracht · Matthias Leschke · Bodo Cremers · Stefan Hardt · Michael Buerke · Hanns Ackermann · Michael Boxberger · Ralf Degenhardt · Bruno Scheller

Received: 19 June 2009 / Accepted: 9 December 2009

Abstract
Background Treatment of lesions in small coronary arteries by percutaneous transluminal coronary intervention is limited by a high recurrence rate. We assessed the use of a paclitaxel-coated balloon in this indication.
Methods One-hundred eighteen patients with stenoses in small coronary vessels were treated by a paclitaxel-coated balloon (3 μg/mm^2). The main inclusion criteria encompassed diameter stenosis of ≥70% and ≤22 mm in length with a vessel diameter of 2.25–2.8 mm. Follow-up angiography was performed at scheduled 6-month post-intervention or whenever driven by clinical or electrocardiographic signs of ischemia. The primary endpoint was angiographic in-segment late lumen loss.
Results Eighty-two of 118 patients (70%) with a vessel diameter of 2.35 ± 0.19 mm were treated with the drug-coated balloon only, while 32 patients required additional stent deployment. The mean in-segment late lumen loss was 0.28 ± 0.53 mm. In patients treated with the drug-coated balloon only, the in-segment late lumen loss was

M. Unverdorben · R. Degenhardt
Institut für Klinische Forschung, Herz- und Kreislaufzentrum, Rotenburg an der Fulda, Germany

F. X. Kleber
Klinik für Innere Medizin, Unfallkrankenhaus Berlin, Charité Universitätsmedizin, Berlin, Germany

H. Heuer
Medizinische Klinik, Kardiologie, St. Johannes Hospital, Dortmund, Germany

H.-R. Figulla
Klinik für Innere Medizin, Universitätsklinikum Jena, Jena, Germany

C. Vallbracht
Kardiologische Klinik, Herz- und Kreislaufzentrum, Rotenburg an der Fulda, Germany

M. Leschke
Klinik für Kardiologie, Pneumologie und Angiologie, Klinikum Esslingen, Esslingen, Germany

B. Cremers · B. Scheller (✉)
Klinik für Innere Medizin III, Universitätsklinikum des Saarlandes, Homburg/Saar, Germany
e-mail: bruno.scheller@uks.eu; inbrsc@uniklinik-saarland.de

S. Hardt
Innere Medizin III, Universitätsklinikum Heidelberg, Heidelberg, Germany

M. Buerke
Universitätsklinik und Poliklinik für Innere Medizin III, Halle, Germany

H. Ackermann
Zentrum für Medizinische Informatik, Abteilung für Biomathematik, Universität Frankfurt/Main, Frankfurt/Main, Germany

M. Boxberger
B. Braun Melsungen AG, Vascular Systems, Berlin, Germany

Published online: 06 January 2010

0.16 ± 0.38 mm. At 12 months, the rate of major adverse cardiac events was 15% which was primarily due to the need for target lesion revascularization in 14 patients (12%). In those with additional bare metal stent implantation geographical mismatch between coated-balloon dilatation and stent implantation was significantly associated with the occurrence of restenosis.

Conclusion Treatment of coronary stenosis in small coronary vessels with the paclitaxel-coated balloon was well tolerated. It may offer an alternative to the implantation of a drug-eluting stent (ClinicalTrials.gov Identifier: NCT00404144).

Keywords Drug-coated balloon · Coronary small vessel · Paclitaxel · Restenosis

Introduction

Treatment of lesions in small coronary arteries by percutaneous transluminal coronary intervention is limited by a high recurrence rate. Despite a reduction of restenosis and reintervention rates by coronary bare metal stents compared to angioplasty alone from 34 to 25% [1] and 23 to 18% [2], respectively, the use of uncoated stents failed to reduce the rate of major adverse cardiac events [1–3]. Coronary brachytherapy has been considered a breakthrough treatment for in-stent restenosis. However, it is limited by the availability and ease of use of the radiotherapeutic armamentarium and an increased rate of thrombotic complications [4, 5].

Patients with percutaneous intervention of small coronary vessels seem to have a greater benefit from drug-eluting stents compared to stenting of large native vessel [6]. However, stent-based local drug delivery might be associated with delayed and incomplete endothelialization and the potential risk of subacute and even late stent thrombosis [7, 8]. First in-man trials with a paclitaxel-coated balloon catheter have shown beneficial effects in the treatment of coronary in-stent restenosis [9] and in peripheral arteries [10].

The aim of the PEPCAD I trial was to investigate the SeQuent® Please balloon catheter (B. Braun, Melsungen, Germany), a second-generation paclitaxel-coated balloon, in the treatment of small vessel coronary artery disease.

Methods

Study design

The study was a prospective non-randomized trial performed at eight German departments of cardiology in Berlin, Dortmund, Jena, Rotenburg an der Fulda, Esslingen, Homburg/Saar, Heidelberg, and Halle. The study was sponsored by B. Braun Melsungen AG, Vascular Systems, Berlin, Germany, the manufacturer of the drug-coated balloon catheter. The sponsor had a role in the design of the study, but neither in the analysis of the results, in the decision to publish, nor in the preparation of the manuscript. An independent clinical research organization (CRO) and core lab vouches for the accuracy and completeness of the data.

The study was performed according to the Declaration of Helsinki and World Health Organization guidelines. Requirements of sections 20–22 of the German Medical Device Law and of the European standard EN 540 were followed. Patients gave written informed consent prior to the procedure. The study was approved by the responsible local ethics committees.

Eligible patients were at least 18 years of age, had clinical evidence of stable or unstable angina or abnormal functional study, and exhibited single de novo lesion in a native coronary artery with a reference diameter between 2.25 and 2.8 mm. Exclusion criteria comprised factors such as an acute myocardial infarction within 48 h preceding the procedure, severe renal insufficiency (GFR < 30 ml/min), known hypersensitivity or contraindication to the required medication, and malignancies with a life expectancy of less than 2 years. Angiographic exclusion criteria encompassed a lesion length of more than 22 mm, stenoses <70% of the luminal diameter, unprotected left main stenosis, lesion with a major side branch (>2 mm), and restenotic lesions.

Interventional procedure

Cardiac catheterization was performed through the femoral artery. Patients received 250 mg of aspirin intravenously, heparin as an initial bolus of 70–200 IU/kg body weight adjusted according to the activated clotting time with a target of 200–250 s, and a loading dose of 300 mg of clopidogrel the day before the procedure or 600 mg immediately before the intervention. Glycoprotein IIb/IIIa antagonists were administered at the operator's discretion. After intracoronary injection of nitroglycerin (100–200 μg), baseline angiography of the target vessel was performed in at least two near-orthogonal views showing the target lesion free of foreshortening and vessel overlap. After assessment of the angiographic inclusion and exclusion criteria, each eligible patient underwent treatment of the target lesion with the paclitaxel-coated balloon catheter (paclitaxel at a dose of 3 μg/mm^2 balloon surface; SeQuent® Please; B. Braun Melsungen, Germany). The recommended inflation time for the drug-coated balloon was ≥30 s. The balloon was inflated one time. During this inflation, more than 90% of the drug is released [9]. The

compliance of the balloon allowed for a diameter range from 2.3 mm (5 atm) till 2.8 mm (15 atm). In the case of high grade elastic recoil or severe dissections, additional implantation of bare metal stents was allowed.

Quantitative coronary angiography

Angiography was performed before, during, and after all interventions, at 6 months, and at ischemia driven unscheduled angiography using identical projections. Quantitative analysis of the coronary angiographic images was performed by an independent core laboratory (Clinical Research Institute, Rotenburg an der Fulda, Germany). The CAAS II system (Pie Medical, The Netherlands) was used for automated contour detection and quantification. Measurements included the stenotic area with measurement from shoulder to shoulder (in-lesion), and the total treated area plus 5 mm of the edges (in-segment). Restenosis was defined as a diameter stenosis of ≥50%.

Follow-up and end points

All patients received ≥100 mg aspirin daily. Clopidogrel (75 mg/day) was given for 1 month following stand-alone drug-coated balloon angioplasty, and for 3 months after additional bare metal stent implantation. Patients underwent clinical observation for a total of 12 months. All end points and adverse events were adjudicated by an independent clinical event committee.

In-segment late lumen loss (the difference between the minimal lumen diameter after the procedure and at 6 months as evaluated by quantitative coronary angiography) was the primary end point. Secondary end points included the rate of restenosis and the rate of the combined clinical events up to 12 months, including stent thrombosis, target-lesion revascularization, myocardial infarction, and death. Stent thrombosis was defined according to the ARC definition [11]. Target-lesion revascularization was defined as either percutaneous reintervention or coronary-artery bypass grafting involving the target lesion. The decision to perform a revascularization procedure was based on symptoms of coronary ischemia, angiographic findings at scheduled or unscheduled follow-up, or both. Myocardial infarction was assumed to have occurred if two of the following five criteria were present: chest pain lasting longer than 30 min; substantial changes on electrocardiography (ECG) that were typical of acute myocardial infarction (an ST-segment elevation of 0.1 mV in at least two adjacent ECG leads or the new occurrence of a complete left bundle-branch block); a substantial increase in the level of creatine kinase or its MB isoform (at least three times the upper normal value); new, clinically significant Q waves; and chest pain leading to angiography up to 6 h after the onset of the chest pain, with angiographic evidence of a totally occluded vessel. Serious adverse events were defined according to international (ICH) guidelines [12].

Statistical analysis

Data were analyzed according to intention-to-treat. An as-treated analysis, e.g., comparing patients treated with the drug-coated balloon only and with additional stent implantation, was performed for descriptive comparison only. Continuous data are expressed as means ± standard deviation. Categorical variables were compared with the two-sided chi-square test, continuous variables with the two-sided Student's *t* test or the Welch's test for unequal variances. Confidence intervals for the difference between proportions were calculated with a normal approximation of the binomial distribution without correction for continuity (StatView 5.0 and BiAS 8.05). A two-sided *P* value of <0.05 was considered to indicate statistical significance.

Results

Patients

One-hundred twenty patients were enrolled in the trial between January and December 2006. Baseline characteristics were typical for patients with diffuse coronary artery disease, including 33% diabetic patients. The mean age of was 68 ± 8 years; 72% were men. Most patients had multi-vessel coronary artery disease. Severity of the lesions was predominantly type B (Table 1).

Angioplasty and angiographic follow-up

The mean vessel diameter was 2.35 ± 0.19 mm with a lesion length of 11.5 ± 4.7 mm. Two patients with severe violation of the protocol were excluded from further analysis (one each with a muscle bridge and an insignificant stenosis with no intervention performed). In four of the 118 patients (3%) the lesion could not be crossed by the study balloon (one B1 lesion and three B2 lesions). Two each of those four patients were treated with a conventional balloon catheter or with oral medication leaving 114 patients who were treated with the drug-coated balloon. The balloon diameter was 2.5 mm in each case. A total of 21 dissections occurred in the 114 patients (18.4%). Eighty-two of the 118 patients (70%) were treated with the drug-coated balloon only, while in 32 patients (27%) elastic recoil (12 patients, 10%) or severe dissection (20 patients, 17%) required additional stent deployment (Table 1).

Table 1 Intention-to-treat analysis

Number of patients	118
Age (years)	68.1 ± 7.9
Male (%)	85 (72.0)
Hypertension (%)	103 (87.3)
Hyperlipidemia (%)	95 (80.5)
Diabetes mellitus/insulin dependent (%)	39 (33.1)/12 (10.2)
CAD	
Single vessel disease (%)	45 (38.1)
Two vessel disease (%)	45 (38.1)
Three vessel disease (%)	28 (23.7)
Lesion location	
LAD (%)	44 (37.3)
CX (%)	53 (44.9)
RCA (%)	21 (17.8)
Lesion type	
Type A (%)	17 (14.4)
Type B1 (%)	71 (60.2)
Type B2 (%)	29 (24.6)
Type C (%)	1 (0.8)
Reference diameter (mm)	2.35 ± 0.19
Lesion length (mm)	11.52 ± 4.73
Minimal lumen diameter before intervention (mm)	0.71 ± 0.24
Minimal lumen diameter post intervention (mm)	1.89 ± 0.31
Acute lumen gain (mm)	1.19 ± 0.36
Deployment pressure (mmHg)	11.5 ± 3.7
Balloon inflation time (s)	55.3 ± 19.9
Balloon length (mm)	16.6 ± 5.2
GP IIb/IIIa antagonists (%)	2 (1.7)
Angiographic follow-up	
Follow-up angiography (%)	105 (89)
Minimal lumen diameter in-lesion/in-segment (mm)	1.57 ± 0.51/1.51 ± 0.50
Late lumen loss in-lesion/in-segment (mm)	0.32 ± 0.56/0.28 ± 0.53
Late lumen loss index in-lesion/in-segment	0.24 ± 0.42/0.22 ± 0.46
Binary restenosis rate in-lesion/in-segment (%)	18 (17.1)/19 (18.1)
Net gain in-lesion/in-segment (mm)	0.87 ± 0.51/0.81 ± 0.51
Clinical follow-up	
Target lesion revascularization (%)	14 (11.9)
Myocardial infarction (not lesion related) (%)	2 (1.7)
Death	0
Stent thrombosis with further PCI in study lesion (%)	2 (1.7)
Target lesion revascularization, myocardial infarction, stent thrombosis, or death (%)	18 (15.3)

Baseline clinical data, procedural data, angiographic findings at intervention and at control angiography after 6 months. Clinical follow-up after 12 months (all patients)

All values are mean ± SD or *N* (%)

CAD coronary artery disease; *RCA* right coronary artery; *CX* left circumflex coronary artery; *LAD* left anterior descending coronary artery; *GP* glycoprotein; *CI* confidence interval

A total of 105 of 118 patients (89%) underwent follow-up angiography after 6.4 ± 1.3 months. 13 patients (11%) declined to undergo angiographic follow-up due to the absence of clinical symptoms. The mean in-segment late lumen loss was 0.28 ± 0.53 mm. Restenosis occurred in 19 of 105 patients (18%) (Table 1).

Clinical follow-up

All patients were available for the clinical 12-month follow-up. No patient died during this time period. One non-ST-elevation myocardial infarction occurred in a patient treated with the drug-coated balloon only. Immediately

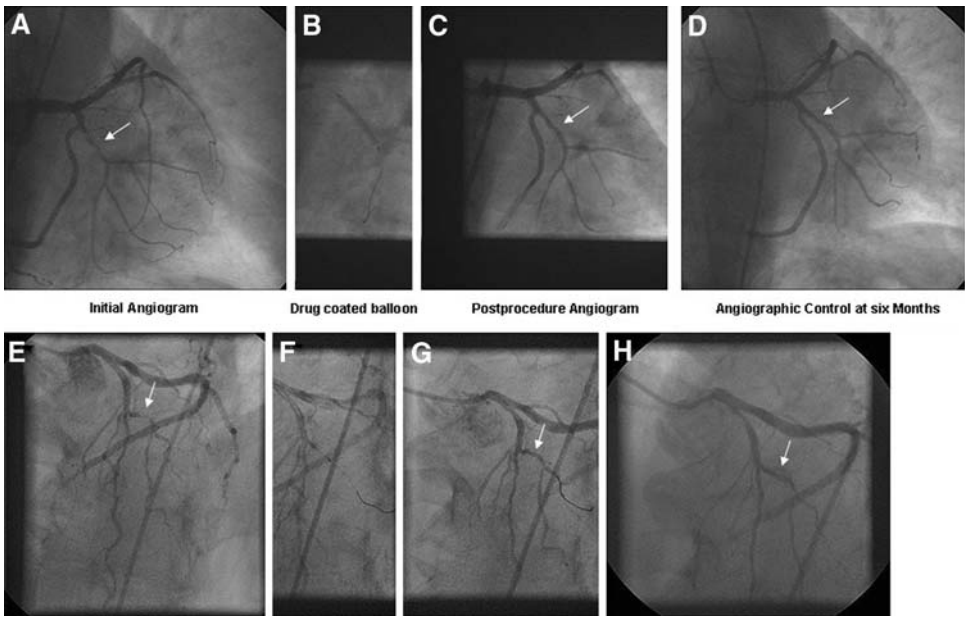

Fig. 1 Angiograms of two study patients with treatment of lesions in small coronary arteries by percutaneous transluminal coronary intervention. Patient 1 was treated with the drug-coated balloon in the circumflex coronary artery: **a** the initial angiogram, **b** the inflation of the drug-coated balloon, **c** the post-procedural angiogram, **d** the 6-month follow-up angiogram free from restenosis. Patient 2 was treated with the drug-coated balloon in the diagonal branch of the left anterior descending coronary artery: **e** the initial angiogram, **f** the inflation of the drug-coated balloon, **g** the post-procedural angiogram, **h** the 6-month follow-up angiogram showing no restenosis

post-PCI, a non-ST-elevation myocardial infarction occurred. However, at scheduled follow-up angiography after 6 months the target vessel and the side branch exhibited only insignificant stenoses. Another patient with additional bare metal stent implantation suffered from a non-ST-elevation myocardial infarction which was related to a high grade lesion in another vessel. Two patients with additional bare metal stent implantation presented with thrombotic occlusion of the stent 2 days and 4 months after the procedure, respectively. The patient with the subacute stent thrombosis was not under dual anti-platelet therapy. In both patients the initial procedure was complicated by geographical mismatch between the drug-coated balloon and the implanted bare metal stent. Fourteen patients (12%) underwent repeated target-lesion revascularization during the 12-month follow-up period (Table 1).

As-treated analysis

In patients treated with the drug-coated balloon only, the in-segment late lumen loss was 0.16 ± 0.38 mm (Fig. 1), in patients with additional bare metal stent implantation 0.62 ± 0.73 mm ($P < 0.0001$). Restenosis occurred in four of 73 patients (6%) in the drug-coated balloon only group and in 13 of 29 patients (45%) in the group with additional bare metal stent implantation ($P < 0.0001$) (Table 2). In patients with additional bare metal stent implantation the total length of the stented area was a predictor for the occurrence of restenosis. In multivariate analysis geographical mismatch between the segments treated with the drug-coated balloon and the areas treated with an uncoated stent was identified as an independent predictor for the incidence of restenosis (Tables 3, 4; Fig. 2). In those patients with the occurrence of restenosis, the stent length was longer than the length of the drug-coated balloon (difference −2.3 ± 10.7 mm), whereas in patients without restenosis the balloons were longer than the stents (difference 2.8 ± 7.7 mm; $P = 0.096$) (Table 3). The in-segment late lumen loss in patients with and without geographical mismatch was 1.00 ± 0.74 and 0.32 ± 0.59 mm, respectively ($P = 0.01$).

The incidence of target lesion revascularization was significantly different between patients treated with the drug-coated balloon only (four of 82 patients, 5%) and those requiring additional bare metal stent implantation (nine of 32 patients, 28%, $P = 0.0005$) (Table 2). The difference in the total clinical event rate (6.1% with drug-coated balloon only vs. 37.5% with additional bare metal stent implantation, $P \leq 0.0001$) was mainly driven by target-lesion revascularization, primarily induced by geographical mismatch in patients with additional bare metal stent implantation.

Discussion

Vessel size represents a major determinant of the outcome after percutaneous coronary intervention. Vessel geometry in small coronary vessels limits compensation for neointimal proliferation after stent implantation. Therefore, conflicting data exist on the superiority of bare metal stent implantation over plain balloon angioplasty in this indication [13–16]. Drug-eluting stents significantly reduce the restenosis rates compared to uncoated stents [17–19]. However, even with drug-eluting stents restenosis rates of up to 31% following the treatment of vessels with diameters of 2.8 mm or less have been reported [20–23].

Table 2 As-treated analysis

	Drug-coated balloon only	Drug-coated balloon + bare metal stent	Difference (95% CI)	*P* value
Number of patients	82	32		
Age (years)	68.8 ± 8	66.3 ± 7.8	2.48 (−0.8 to 5.8)	0.14
Male (%)	56 (68.3)	25 (78.1)	−0.10 (−0.27 to 0.08)	0.30
Hypertension (%)	75 (91.5)	26 (81.3)	0.10 (−0.02 to 0.22)	0.12
Hyperlipidemia (%)	66 (80.5)	26 (81.3)	−0.01 (−0.17 to 0.15)	0.93
Diabetes mellitus (%)	31 (37.8)	6 (18.8)	0.19 (0.02–0.36)	0.05
Insulin dependent (%)	10/31 (32.3)	1/6 (16.7)	0.16 (−0.18 to 0.50)	0.44
CAD				
Single vessel disease (%)	35 (42.7)	10 (31.3)		0.17
Two vessel disease (%)	32 (39.0)	11(34.4)		
Three vessel disease (%)	15 (18.3)	11(34.4)		
Lesion location				
LAD (%)	31 (37.8)	13 (40.6)		0.96
CX (%)	37 (45.1)	14 (43.8)		
RCA (%)	14 (17.1)	5 (15.6)		
Type of lesion				
Type A (%)	11 (13.4)	6 (18.8)		0.60
Type B1 (%)	53 (64.6)	17 (53.1)		
Type B2 (%)	17 (20.7)	9 (28.1)		
Type C (%)	1 (1.2)	0 (0)		
Reference diameter (mm)	2.36 ± 0.18	2.33 ± 020	0.03 (−0.05 to 0.11)	0.48
Lesion length (mm)	11.27 ± 4.3	11.52 ± 5.5	−0.25 (−0.22 to 1.67)	0.80
Minimal lumen diameter before intervention (mm)	0.72 ± 0.25	0.71 ± 0.20	0.01 (−0.09 to 0.11)	0.85
Minimal lumen diameter post intervention	1.87 ± 0.21	2.05 ± 0.06	−0.18 (−0.28 to −0.08)	0.0003
Acute lumen gain	1.16 ± 0.33	1.35 ± 0.31	−0.19 (−0.33 to −0.06)	0.005
Deployment pressure (mmHg)	11.9 ± 3.0	11.9 ± 3.0	0.0 (−1.2 to 1.3)	0.98
Balloon inflation time (s)	58.4 ± 17.1	54.5 ± 17.6	3.9 (−3.2 to 11.0)	0.28
Balloon length (mm)	16.2 ± 5.0	17.0 ± 5.4	−0.7 (−2.9 to 1.4)	0.48
GP IIb/IIIa antagonists (%)	1 (1.2)	1 (3.1)	−0.02 (−0.08 to 0.05)	0.48
Angiographic Follow-up				
Follow-up angiography (%)	73 (89)	29 (90.6)	−0.02 (−0.14 to 0.11)	0.80
Minimal lumen diameter				
In-lesion (mm)	1.68 ± 0.34	1.35 ± 0.72	0.34 (0.13–0.55)	0.002
In-segment (mm)	1.63 ± 0.32	1.28 ± 0.71	0.36 (0.16–0.56)	0.0006
Late lumen loss				
In-lesion (mm)	0.18 ± 0.38	0.73 ± 0.74	−0.55 (−0.77 to −0.33)	<0.0001
In-segment (mm)	0.16 ± 0.38	0.62 ± 0.73	−0.45 (−0.67 to −0.23)	<0.0001
Late lumen loss index				
In-lesion	0.13 ± 0.29	0.51 ± 0.52	−0.38 (−0.55 to −0.22	<0.0001
In-segment	0.12 ± 0.31	0.49 ± 0.63	−0.37 (−0.56 to −0.19)	0.0001
Binary restenosis rate				
In-lesion (%)	4 (5.5)	12 (41.3)	−0.36 (−0.55 to −0.17)	<0.0001
In-segment (%)	4 (5.5)	13 (44.8)	−0.39 (−0.58 to −0.21)	<0.0001
Net gain				
In-lesion (mm)	0.98 ± 0.38	0.64 ± 0.48	0.34 (0.13–0.55)	0.002
In-segment (mm)	0.93 ± 0.37	0.57 ± 0.68	0.36 (0.15–0.57)	0.0009

Table 2 continued

	Drug-coated balloon only	Drug-coated balloon + bare metal stent	Difference (95% CI)	*P* value
Clinical follow-up				
Target lesion revascularization (%)	4 (4.9)	9 (28.1)	−0.23 (−0.40 to −0.07)	0.0005
Myocardial infarction (%)	1 (1.3)	1 (3.1)	−0.02 (−0.08 to 0.04)	0.49
Death	0	0		
Stent thrombosis (%)	0	2(6.3)	−0.06 (−0.15 to 0.02)	0.14
Target lesion revascularization, myocardial infarction, stent thrombosis, or death (%)	5 (6.1)	12 (37.5)	−0.31 (−0.49 to −0.14)	<0.0001

Baseline clinical data, procedural data, angiographic findings at intervention and at control angiography after 6 months. Clinical follow-up after 12 months (patients treated with drug-coated balloon only and with additional bare metal stent implantation)

All values are mean ± SD or *N* (%)

CAD coronary artery disease; *RCA* right coronary artery; *CX* left circumflex coronary artery; *LAD* left anterior descending coronary artery; *GP* glycoprotein; *CI* confidence interval

Table 3 Univariate analysis of factors predicting the occurrence of restenosis in patients with additional bare metal stent implantation

	Patients with restenosis	Patients without restenosis	*P* value
Number of patients	13	16	
Geographical mismatch (%)	10 (77)	3 (19)	0.029
Total stent length (mm)	19.4 ± 8.4	14.4 ± 10.2	0.035
Drug-coated balloon length – stent length (mm)	−2.31 ± 10.72	2.75 ± 7.71	0.096
Lesion length (mm)	12.9 ± 7.1	10.5 ± 4.0	0.83
Minimal lumen diameter before intervention (mm)	0.67 ± 0.21	0.74 ± 0.22	0.41
Acute gain (mm)	1.42 ± 0.29	1.33 ± 0.35	0.26
Deployment pressure stent (atm)	12.2 ± 2.8	13.8 ± 4.4	0.28
Diabetes mellitus (%)	4 (31)	2 (13)	0.36
Inflation pressure drug-coated balloon (atm)	11.5 ± 2.4	12.6 ± 3.2	0.37
Duration of inflation drug-coated balloon (s)	51.9 ± 12.2	56.3 ± 22.4	0.43
Diameter stenosis before intervention (%)	70.9 ± 8.4	68.8 ± 8.5	0.63
Reference diameter (mm)	2.32 ± 0.26	2.35 ± 0.17	0.98
Previous myocardial infarction (%)	4 (31)	4 (25)	1

Table 4 Multivariate analysis of factors predicting the occurrence of restenosis in patients with additional bare metal stent implantation

	Patients with restenosis	Patients without restenosis	*P* value
Number of patients	13	16	
Geographical mismatch (%)	10 (77)	3 (19)	0.026
Drug-coated balloon length – stent length (mm)	−2.31 ± 10.72	2.75 ± 7.71	0.39
Total stent length (mm)	19.4 ± 8.4	14.4 ± 10.2	0.49
Lesion length (mm)	12.9 ± 7.1	10.5 ± 4.0	0.11
Minimal lumen diameter before intervention (mm)	0.67 ± 0.21	0.74 ± 0.22	0.26
Acute gain (mm)	1.42 ± 0.29	1.33 ± 0.35	0.49
Diabetes mellitus (%)	4 (31)	2 (13)	0.16
Inflation pressure drug-coated balloon (atm)	11.5 ± 2.4	12.6 ± 3.2	0.23

Paclitaxel-coated angioplasty balloon catheters based on a new matrix coating technique have shown reproducible efficacy in the treatment and prevention of restenosis in the porcine coronary model [24–26], in coronary in-stent restenosis in patients [9, 27, 28], and in human peripheral arteries [10, 29]. The coating includes an X-ray contrast

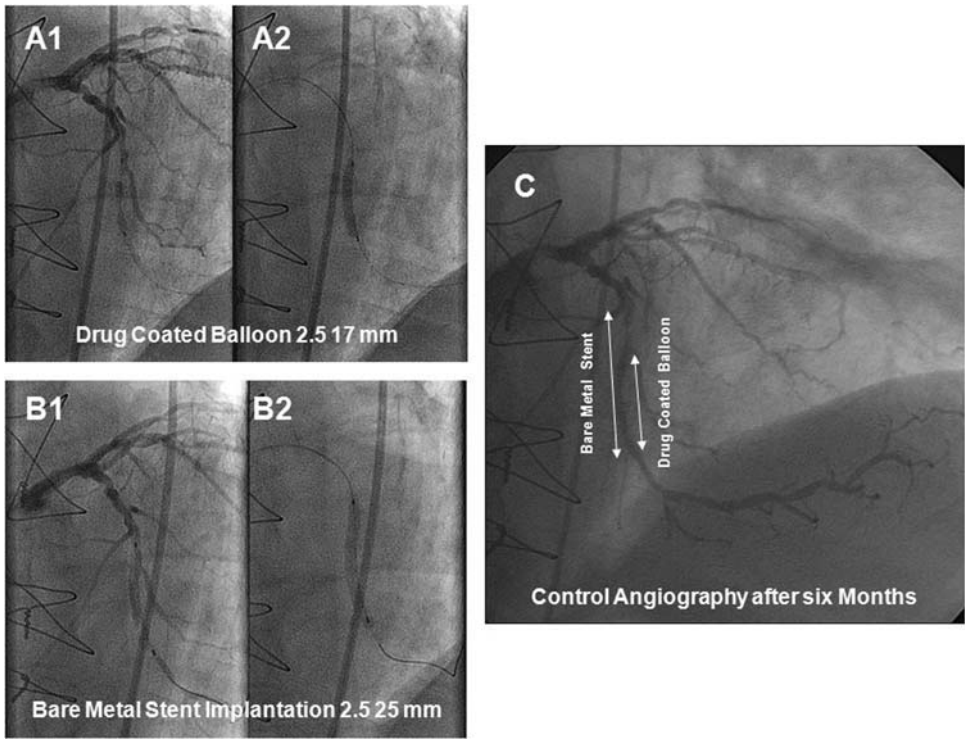

Fig. 2 Angiograms of a patient with treatment of a lesion in a small circumflex coronary artery by percutaneous transluminal coronary intervention. *A1* The initial angiogram, *A2* the inflation of the drug-coated balloon (diameter 2.5 mm, length 17 mm), *B1* a severe dissection after angioplasty, *B2* the implantation of a bare metal stent (diameter 25 mm, length 25 mm). *C* The 6-month follow-up angiograms showing no restenosis in the area pretreated with the drug-eluting balloon while in the segment treated with the bare metal stent only a significant restenosis occurred

medium (iopromide) which improves the solubility of the drug and its transfer to the vessel wall [24, 30]. In view of these favorable results, it is assumed that the drug-coated balloon may also have beneficial effects in the treatment of de-novo coronary narrowing, especially in high risk lesion subsets such as small vessel disease.

In the present study, late lumen loss and binary restenosis rates compare well with recently published data on drug-eluting stents in small coronary vessel disease [18–23]. Patients treated with the drug-coated balloon only presented with a binary restenosis rate of 6% in vessels with an average vessel diameter of less than 2.4 mm. In this patient subset, binary restenosis rates of 20–31% have been reported for drug-eluting stents [21, 22]. The target lesion resvascularization rate of 5% in patients treated with the drug-coated balloon only compares well with only clinically driven rates of sirolimus-eluting stents [23]. In several animal trials, a maximum effective paclitaxel concentration of 3 μg/mm^2 balloon surface was identified [24–26]. In contrast to earlier clinical trials [9, 27], recommended balloon inflation time was reduced from 60 to 30 s based on recent results from animal trials showing similar reduction in neointimal area with balloon inflation times ranging from 10 s to 2 min [26].

Earlier trials in coronary artery small vessel disease reported cross-over rates to additional stent implantation in the angioplasty groups from 16 to 40% [13–16]. In the present trial, after drug-coated balloon angioplasty, 28% of the patients underwent bare metal stent implantation due to acute elastic recoil or severe dissections. A major limitation of this study represents the high incidence of geographical mismatch in patients with additional implantation of a bare metal stent after pre-treatment with the drug-coated balloon. Geographical mismatch implicates that the bare metal stent was in part deployed in vessel areas not previously treated with the drug-coated balloon, a problem which has not been addressed in the study protocol. The observed restenosis rate of 19% in the subgroup of patients without geographical mismatch compares well with the corresponding rates for drug-eluting stents [22]. However, this comparison is further limited by the low number of patients in this subgroup.

Drug-eluting stents are characterized by a long lasting release of antiproliferative agents from the stent struts resulting in delayed or missing endothelialization and possible local inflammation due to polymeric coatings [7, 31]. Therefore, dual antiplatelet therapy after implantation of a drug-eluting stent is recommended for 12 months by current guidelines [32]. The concept of a drug-coated balloon allows for a homogenous drug application to the arterial wall. It avoids a long lasting drug exposition of stent struts and the use of polymers. In the present study clopidogrel was only given for 1 month following drug-coated balloon angioplasty alone and for 3 months after additional bare metal stent implantation.

The present study supports the concept of non-stent based intravascular local drug delivery by matrix-coated angioplasty balloon catheters based on the PACCOCATH

technology. The findings of trials using this technology compare well with another non-stent based approach, the concept of drug delivery with double-balloon catheters. The recently published randomized LOCAL TAX trial demonstrated clinical efficacy of local delivery of fluid paclitaxel after bare metal stent implantation [33].

PEPCAD I is the first trial using a drug-coated balloon in de novo coronary narrowing in a high-risk patient population. The study is limited by the fact that it was conducted in an uncontrolled fashion. However, the results encourage a randomized trial comparing the drug-coated balloon with drug-eluting stents in small coronary vessel disease and other high-risk de novo lesions. Theoretically, long balloon inflation times could cause myocardial injury. Compared to earlier trials [9, 27], recommended balloon inflation times were reduced from 60 to 30 s. Another limitation of this trial represents the angiographic follow-up rate of 89%.

Acknowledgments The study was supported by B. Braun Melsungen, Germany. Dr. Unverdorben receives salaries from the Institut für Klinische Forschung, Herz- und Kreislaufzentrum, Rotenburg an der Fulda, Germany; end of 2008 (after finishing this trial) he became an employee of B. Braun USA (orthopedics and medical affairs). Prof. Scheller reports being co-inventor of a patent application for various methods of restenosis inhibition, including the technique employed in this trial, by Charité University Hospital, Berlin.

Appendix: PEPCAD I Study Group

Principal Investigator: Martin Unverdorben, Institut für Klinische Forschung, Herz- und Kreislaufzentrum, Rotenburg an der Fulda, Germany

CRO and Angiographic Core Lab: Ralf Degenhardt, Institut für Klinische Forschung, Herz- und Kreislaufzentrum, Rotenburg an der Fulda, Germany. Staff: Tina Iffland, Melanie Häußler

Statistical Advisor: Hanns Ackermann, Zentrum für medizinische Informatik, Abteilung für Biomathematik, Universität Frankfurt/Main, Germany

Klinik für Innere Medizin, Unfallkrankenhaus Berlin, Charité Universitätsmedizin, Berlin, Germany: Franz X. Kleber, Sascha Rux, Daniel Grund; Heike Bull; 50 patients

Medizinische Klinik, Kardiologie, St. Johannes Hospital, Dortmund, Germany: Hubertus Heuer, Norbert Schulze Waltrup, Joachim Weber-Albers, Maritta Marks, Axel Bünemann, Dietmar Schmitz, Mathias Stratmann; Martin Schulz, Claudia Rosendahl, Birgit Laschewski, Alexandra Thrun, Kathrin Euler, Ute Dieckheuer; 35 patients

Klinik für Innere Medizin, Universitätsklinikum Jena, Germany: Stefan Betge, Hans-Reiner Figulla; 13 patients

Kardiologische Klinik, Herz- und Kreislaufzentrum, Rotenburg an der Fulda, Germany: Christian Vallbracht, Manfred Scholz, Henning Köhler, Bernd Abt, Eberhard Wagner; seven patients

Klinik für Kardiologie, Pneumologie und Angiologie, Klinikum Esslingen, Germany: Matthias Leschke, Jean Rieber; Birgit Blaich; eight patients

Klinik für Innere Medizin III, Universitätsklinikum des Saarlandes, Homburg/Saar, Germany: Bruno Scheller, Bodo Cremers, Michael Kindermann, Michael Böhm; Nicole Hollinger, Bianca Werner; four patients

Innere Medizin III, Universitätsklinikum Heidelberg, Germany: Helmut Kücherer, Stefan Hardt; Christiane Selter; two patients

Universitätsklinik und Poliklinik für Innere Medizin III, Halle, Germany: Michael Buerke; Michaela König; one patient

References

1. Moreno R, Fernández C, Alfonso F, Hernández R, Pérez-Vizcayno MJ, Escaned J, Sabaté M, Bañuelos C, Angiolillo DJ, Azcona L, Macaya C (2004) Coronary stenting versus balloon angioplasty in small vessels: a meta-analysis from 11 randomized studies. J Am Coll Cardiol 43:1964–1972
2. Agostoni P, Biondi-Zoccai GG, Gasparini GL, Anselmi M, Morando G, Turri M, Abbate A, McFadden EP, Vassanelli C, Zardini P, Colombo A, Serruys PW (2005) Is bare-metal stenting superior to balloon angioplasty for small vessel coronary artery disease? Evidence from a meta-analysis of randomized trials. Eur Heart J 26:881–889
3. Hausleiter J, Kastrati A, Mehilli J, Schühlen H, Pache J, Dotzer F, Dirschinger J, Schömig A (2002) Predictive factors for early cardiac events and angiographic restenosis after coronary stent placement in small coronary arteries. J Am Coll Cardiol 40:882–889
4. Waksman R (1999) Late thrombosis after radiation. Sitting on a time bomb. Circulation 100:780–782
5. Verin V, Popowski Y, de Bruyne B, Baumgart D, Sauerwein W, Lins M, Kovacs G, Thomas M, Calman F, Disco C, Serruys PW, Wijns W, Dose-Finding Study Group (2001) Endoluminal beta-radiation therapy for the prevention of coronary restenosis after balloon angioplasty. The Dose-Finding Study Group. N Engl J Med 344:243–249
6. Brunner-La Rocca HP, Kaiser C, Pfisterer M (2007) BASKET Investigators. Targeted stent use in clinical practice based on evidence from the Basel Stent Cost Effectiveness Trial (BASKET). Eur Heart J 28:719–725
7. Joner M, Finn AV, Farb A, Mont EK, Kolodgie FD, Ladich E, Kutys R, Skorija K, Gold HK, Virmani R (2006) Pathology of drug-eluting stents in humans: delayed healing and late thrombotic risk. J Am Coll Cardiol 48:193–202
8. Carlsson J, von Wagenheim B, Linder R, Anwari TM, Qvist J, Petersson I, Magounakis T, Lagerqvist B (2007) Is late stent thrombosis in drug-eluting stents a real clinical issue? A single-center experience and review of the literature. Clin Res Cardiol 96:86–93
9. Scheller B, Hehrlein C, Bocksch W, Rutsch W, Haghi D, Dietz U, Böhm M, Speck U (2006) Treatment of in-stent restenosis with a paclitaxel-coated balloon catheter. N Engl J Med 355:2113–2124

10. Tepe G, Zeller T, Albrecht T, Heller S, Schwarzwälder U, Beregi JP, Claussen CD, Oldenburg A, Scheller B, Speck U (2008) Local taxane with short exposure for reduction of restenosis in distal arteries: THUNDER trial. N Engl J Med 358:689–699
11. Cutlip DE, Windecker S, Mehran R et al (2007) Clinical end points in coronary stent trials: a case for standardized definitions. Circulation 115:2344–2351
12. ICH Harmonized Tripartite Guideline (1994) Clinical safety data management: definitions and standards for expedited reporting E2A. International conference on harmonisation of technical requirements for registration of pharmaceuticals for human use, October 1994. Available at: http://www.ich.org/LOB/media/MEDIA436.pdf. Accessed 23 Jun 2006
13. Park SW, Lee CW, Hong MK, Kim JJ, Cho GY, Nah DY, Park SJ (2000) Randomized comparison of coronary stenting with optimal balloon angioplasty for treatment of lesions in small coronary arteries. Eur Heart J 21:1785–1789
14. Kastrati A, Schömig A, Dirschinger J, Mehilli J, Dotzer F, von Welser N, Neumann FJ (2000) A randomized trial comparing stenting with balloon angioplasty in small vessels in patients with symptomatic coronary artery disease. ISAR-SMART Study Investigators. Intracoronary Stenting or Angioplasty for Restenosis Reduction in Small Arteries. Circulation 102:2593–2598
15. Koning R, Chan C, Eltchaninoff H, Tron C, Janorkar S, Gupta V, Cribier A (1998) Primary stenting of de novo lesions in small coronary arteries: a prospective, pilot study. Cathet Cardiovasc Diagn 45:235–238
16. Hausleiter J, Kastrati A, Mehilli J, Schühlen H, Pache J, Dotzer F, Glatthor C, Siebert S, Dirschinger J, Schömig A (2004) ISAR-SMART-2 Investigators. A randomized trial comparing phosphorylcholine-coated stenting with balloon angioplasty as well as abciximab with placebo for restenosis reduction in small coronary arteries. J Intern Med 256:388–397
17. Schofer J, Schluter M, Gershlick AH, Wijns W, Garcia E, Schampaert E, Breithardt G (2003) Sirolimus-eluting stents for treatment of patients with long atherosclerotic lesions in small coronary arteries: double-blind, randomised controlled trial (E-SIRIUS). Lancet 362:1093–1099
18. Ardissino D, Cavallini C, Bramucci E, Indolfi C, Marzocchi A, Manari A, Angeloni G, Carosio G, Bonizzoni E, Colusso S, Repetto M, Merlini PA (2004) SES-SMART Investigators. Sirolimus-eluting vs uncoated stents for prevention of restenosis in small coronary arteries: a randomized trial. JAMA 292:2727–2734
19. Mehilli J, Dibra A, Kastrati A, Pache J, Dirschinger J, Schömig A (2006) Intracoronary Drug-Eluting Stenting to Abrogate Restenosis in Small Arteries (ISAR-SMART 3) Study Investigators. Eur Heart J 27:260–266
20. Morice MC, Colombo A, Meier B, Serruys P, Tamburino C, Guagliumi G, Sousa E, Stoll HP, REALITY Trial Investigators (2006) Sirolimus- vs paclitaxel-eluting stents in de novo coronary artery lesions: the REALITY trial: a randomized controlled trial. JAMA 295:895–904
21. Stone GW, Ellis SG, Cannon L, Mann JT, Greenberg JD, Spriggs D, O'Shaughnessy CD, DeMaio S, Hall P, Popma JP, Koglin J, Russell ME, for the TAXUS V Investigators (2005) Comparison of a polymer-based paclitaxel-eluting stent with a bare metal stent in patients with complex coronary artery disease. A randomized controlled trial. JAMA 294:1215–1223
22. Elezi S, Dibra A, Mehilli J, Pache J, Wessely R, Schömig A, Kastrati A (2006) Vessel size and outcome after coronary drug-eluting stent placement: results from a large cohort of patients treated with sirolimus- or paclitaxel-eluting stents. J Am Coll Cardiol 48:1304–1309
23. Tanimoto S, Daemen J, Tsuchida K, García-García HM, de Jaegere P, van Domburg RT, Serruys PW (2007) Two-year clinical outcome after coronary stenting of small vessels using 2.25-mm sirolimus- and paclitaxel-eluting stents: insight into the RESEARCH and T-SEARCH registries. Catheter Cardiovasc Interv 69(1):94–103
24. Scheller B, Speck U, Abramjuk C, Bernhardt U, Böhm M, Nickenig G (2004) Paclitaxel balloon coating—a novel method for prevention and therapy of restenosis. Circulation 110:810–814
25. Speck U, Scheller B, Abramjuk C, Breitwieser C, Dobberstein J, Böhm M, Hamm B (2006) Neointima inhibition: comparison of effectiveness of non-stent-based local drug delivery and a drug-eluting stent in porcine coronary arteries. Radiology 240:411–418
26. Cremers C, Speck U, Kaufels N, Mahnkopf D, Kühler M, Böhm M (2009) Scheller B: drug-eluting balloon: very short-term exposure and overlapping. Thromb Haemost 101:201–206
27. Scheller B, Hehrlein C, Bocksch W, Rutsch W, Haghi D, Dietz U, Böhm M, Speck U (2008) Two year follow-up after treatment of coronary in-stent restenosis with a paclitaxel-coated balloon catheter. Clin Res Cardiol 97:773–781
28. Unverdorben M, Vallbracht C, Heuer H, Hengstenberg C, Maikowski C, Werner GS, Antoni D, Kleber FX, Bocksch W, Leschke M, Ackermann H, Boxberger M, Speck U, Degenhardt R, Scheller B (2009) Paclitaxel-coated balloon catheter versus paclitaxel-coated stent for the treatment of coronary in-stent restenosis. Circulation 119:2986–2994
29. Werk M, Langner S, Reinkensmeier B, Boettcher HF, Tepe G, Dietz U, Hosten N, Hamm B, Speck U, Ricke J (2008) Inhibition of restenosis in femoropopliteal arteries: paclitaxel-coated versus uncoated balloon—FemPac randomized pilot trial. Circulation 118:1358–1365
30. Scheller B, Speck U, Böhm M (2007) Prevention of restenosis—is angioplasty the answer? Heart 93:539–541
31. Virmani R, Guagliumi G, Farb A, Musumeci G, Grieco N, Motta T, Mihalcsik L, Tespili M, Valsecchi O, Kolodgie FD (2004) Localized hypersensitivity and late coronary thrombosis secondary to a sirolimus-eluting stent: should we be cautious? Circulation 109:701–705
32. King SB 3rd, Smith SC Jr, Hirshfeld JW Jr, Jacobs AK, Morrison DA, Williams DO, WRITING COMMITTEE MEMBERS, Feldman TE, Kern MJ, O'Neill WW, Schaff HV, Whitlow PL, Adams CD, Anderson JL, Buller CE, Creager MA, Ettinger SM, Halperin JL, Hunt SA, Krumholz HM, Kushner FG, Lytle BW, Nishimura R, Page RL, Riegel B, Tarkington LG, Yancy CW (2008) 2007 Focused Update of the ACC/AHA/SCAI 2005 Guideline Update for Percutaneous Coronary Intervention: a report of the American College of Cardiology/American Heart Association Task Force on Practice Guidelines: 2007 Writing Group to Review New Evidence and Update the ACC/AHA/SCAI 2005 Guideline Update for Percutaneous Coronary Intervention, Writing on Behalf of the 2005 Writing Committee. Circulation 117:261–295
33. Herdeg C, Göhring-Frischholz K, Haase KK, Geisler T, Zürn C, Hartmann U, Wöhrle J, Nusser T, Dippon J, May AE, Gawaz M (2009) Catheter-based delivery of fluid paclitaxel for prevention of restenosis in native coronary artery lesions after stent implantation. Circ Cardiovasc Intervent 2:294–301