



CLINICAL EVIDENCE FOLDER Eso-SPONGE®

ENDOLUMINAL VACUUM THERAPY FOR THE TREATMENT
OF OESOPHAGEAL ANASTOMOTIC LEAKAGE

CONTENT

3 RATIONALE

6 CLINICAL EVIDENCE

16 KEY MESSAGES

18 ABSTRACTS

32 REFERENCES

RATIONALE

According to the Robert Koch Institute (RKI), the number of new cases suffering of a esophageal carcinoma has doubled since 1990 in Germany. The older age groups were more affected. Taking into account an unchanged morbidity rate and survival rate a further increase of 10-year prevalence rate is expected in the coming years to 10.500 patients. In contrast to esophageal cancer, the incidence of gastric cancer is declining since 1990. When adopting consistent incidence and survival rates, the RKI counted with a 10-year prevalence of 56.000 gastric cancer patients for the next years¹. Both the esophageal resection and the gastrectomy is accompanied with a high complication rate².

The most serious complication is an anastomosis leakage. In the literature insufficiency rates up to 30 % have been reported after esophagectomy³. An anastomosis leakage rate up to 10 % is recorded after gastrectomy and distal esophagectomy⁴. For large intrathoracic or intra-abdominal insufficiencies, mortality rates of up to 50 % have been observed⁵. The most responsible factor that leading to death after anastomosis leakage and perforation is the development of the mediastinitis. Next to the surgical revision and endoscopic stent system nowadays the endoluminal vacuum sponge therapy is available for the treatment of anastomosis insufficiencies. The surgical intervention consists of the surgical debridement, the closure of the dehiscence and the new construction of the anastomosis with adequate drainage. The conservative treatment is the endoscopic closure by clips or the injection of fibrin glue or endoscopic stent application or the endoluminal vacuum sponge drainage⁶⁻⁹.

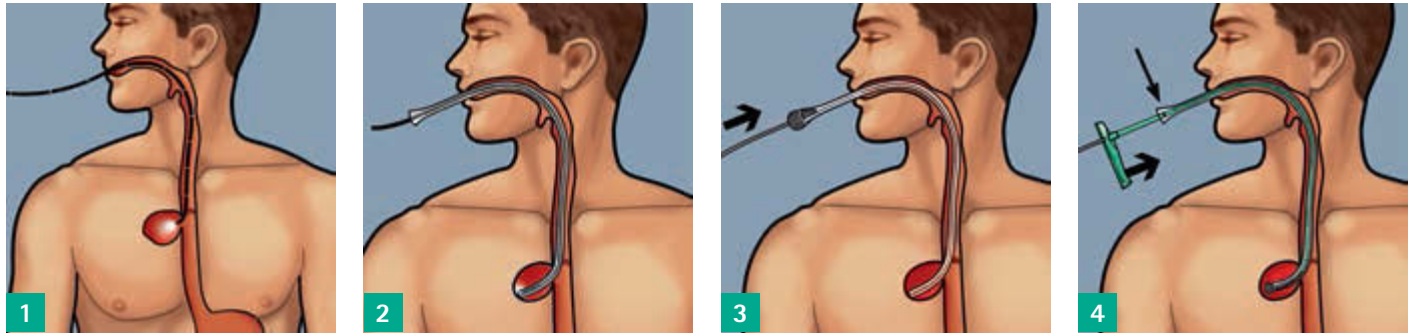
So far, several case series that include up to 30 patients, have been carried out using homemade endoluminal vacuum sponge systems to treat anastomosis insufficiencies in the upper gastrointestinal tract (GIT)¹⁰. Within these case series the sponge is endoscopic applied either intraluminal or intracavitary and the sponge is connected to a negative pressure of 125 mmHg via a drainage hose. The drainage hose is diverted transnasal. The size of the sponge is adapted to the cavity. The sponges are changed every 48-72 hours until granulated tissue has been developed. The therapy is stopped as far as the defect reached a size which is too small for a further sponge insertion or until the cavity is completely closed or collapsed. The enteral nutrition of the patient is usually performed with a feeding tube, or percutaneous endoscopic gastrostomy (PEG) or orally.

RATIONALE

The published clinical results are promising. Thus, the mortality rate lies between 0–16.7 % in these pilot studies which is well below the mortality rates described for other treatment methods^{11–18}. Two authors have compared the endoscopic stent insertion with the endoluminal vacuum therapy and indicated that the stent endoluminal vacuum therapy was superior in comparison to the stent application^{17,18}. Brangewitz et al.¹⁷ could show that the healing rate was obviously higher in patients treated with the vacuum sponge therapy compared to patients receiving stent application (84.4 % vs. 53.8 %). A higher esophageal stricture rate after stent therapy was seen as well (28.2 % vs. 9.4 %). In addition Schniewind et al.¹⁸ observed a higher mortality rate in the stent group as in the endoluminal vacuum therapy group (50 % vs. 12 %). Possible complications after endoluminal vacuum therapy are bleedings from blood vessels erosions or the development of esophageal fistulas, but these have rarely been described^{10,11,12,17}. Potential risks which are mentioned for the endoscopic stent applications are as follows: stent stenosis, stent migration, stent dislocation, ingrowth of the stent, perforations induced by the stent and a lacking sealing^{17,18}. In most of the performed case series the endoluminal vacuum therapy is described as a safe and simple minimal invasive approach leading to low mortality rate with an excellent clinical outcome^{11,13,16,19}.

Since July 2014 the first commercially purchasable endoluminal vacuum sponge system (Eso-SPONGE®) of B. Braun is available for the conservative endoscopic treatment of anastomosis insufficiency within the upper GIT. Eso-SPONGE® is CE certified and already used in many hospitals for the treatment of perforations and anastomotic leaks. To evaluate the performance of Eso-SPONGE® in the upper gastrointestinal tract (GIT), a multicenter, prospective, web-based online registry was initiated in collaboration with the University Schleswig Holstein, Department of General, Visceral, Thoracic, Transplantation and Pediatric Surgery, Prof. C. Schafmayer. The registry is used for the systematic collection of clinical data for Eso-SPONGE® used in clinical routine. The registry allows the detailed documentation of the anamnesis, the outcome of endoluminal vacuum treatment and possible complications occurring during therapy. After the first inclusions a success rate of 95 % could be observed. A detailed description of the Eso-SPONGE® registry can be found in Clinical Evidence chapter of this folder.

Figure 1: Schema Eso-SPONGE® treatment

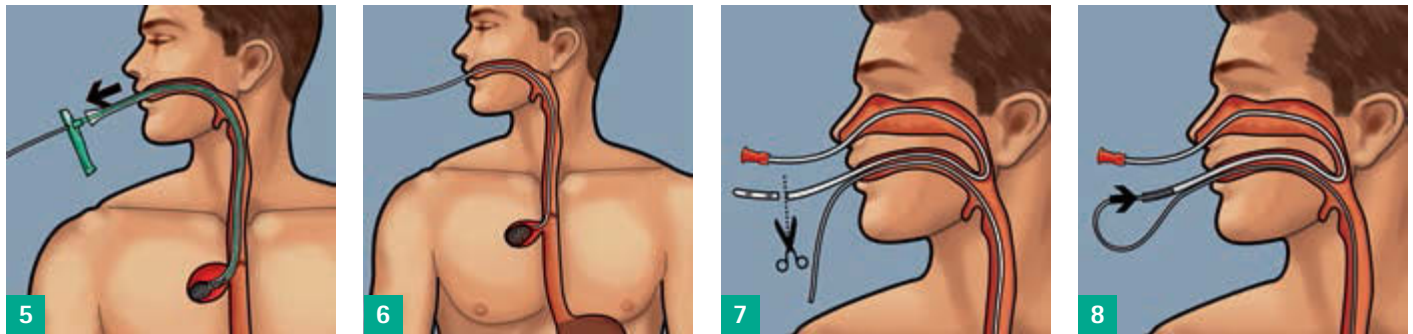


1
Before use:
Investigate and measure the wound cavity with a flexible endoscope.

2
Introduce the oesophageal overtube under visual control into the insufficiency hole. The endoscope can be used as a guide rail here.

3
Cover the appropriate, tailored Eso-SPONGE®, with sterile hydrogel (glycerol based) and introduce it into the overtube.

4
Push the Eso-SPONGE® to the mark with the pusher. The sponge is now at the end of the overtube.

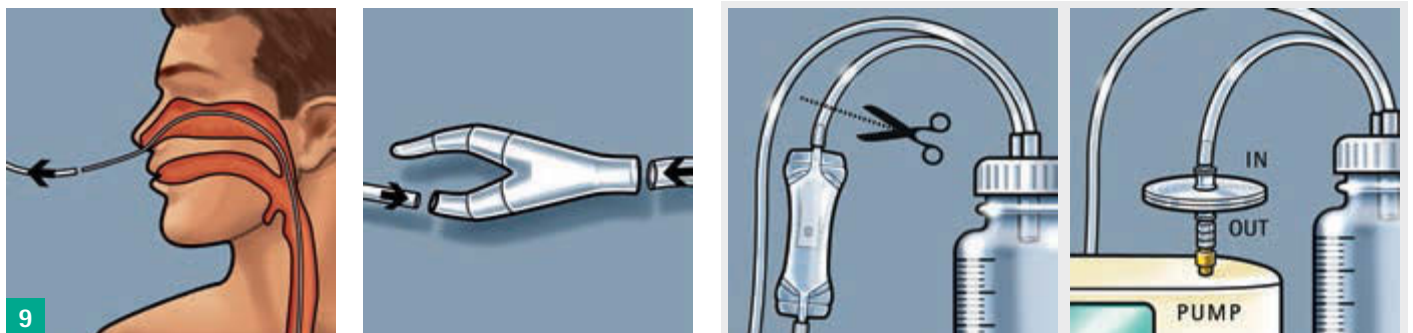


5
Hold the pusher in place and pull the overtube out as far as the handle of the pusher. The sponge will unfold in the insufficiency hole; the overtube and pusher can be removed together.

6
Endoscopic position control of the sponge and appropriate correction by means of endoscopic grasping forceps.

7
Transnasal channelling:
Insert stomach tube CH 16 (not included in the set) through the nose and bring it out through the mouth. Cut off the atraumatic tip.

8
Connect the drain with the stomach tube outside the mouth. Pull the stomach tube together with the drain back through the nose.



9
The drain is now transnasally channelled.

Connect the drain by means of the y-piece to the hose of an adjustable, medical pump with sufficient suction performance.* Activate the pump, where necessary keeping endoscopic visual control of the sponge.

When using the MV 1 pump (MTG Germany): Cut off the secret valve from the secretion cylinder hose.

Connect the filters using a Luer Lock to the pump and attach the cylinder hose to the filter.

* Use an adjustable, medical pump with a suction of between 50 and a maximum of 125 mmHg. Regular checking of the system is mandatory. The system must be **changed every 48-72 hours** and, where appropriate, a new sponge inserted.

CLINICAL EVIDENCE

ENDOLUMINAL VACUUM THERAPY FOR THE TREATMENT OF ANASTOMOSIS INSUFFICIENCY OR PERFORATION WITHIN THE UPPER GIT.

COHORT STUDIES

The clinical effectiveness of the product Eso-SPONGE® for the treatment of perforations and anastomosis insufficiencies within the upper GIT is currently evaluated in a registry (**Eso-SPONGE® Registry**). In November 2014, the ethics approval of the committee of the Christian Albrechts University in Kiel was obtained for the implementation of the registry. Aim of the registry is the systematic collection of clinical data on the performance of Eso-SPONGE® under daily clinical routine. In collaboration with the University Hospital Schleswig-Holstein, Department of General, Visceral, Thoracic, Transplantation and Pediatric Surgery, Prof. C. Schafmayer a multicenter, prospective, web-based online registry was established.

Studies Portal | Deutsch | English | Francais | Español

Welcome to our online database for the documentation of your clinical results!

Dear User, Log-in access to the Internet portal has changed.

If you are logging in for the first time, this system will ask you to change your password. This is to increase the security of the portal. After you have logged in successfully, you will be able to see the databases for which you currently have access rights. You can change your password at any time, but you should change it after 6 months at the latest.

Login

User name:

Password:

Change password

User name:

Old password:

New password:

New password (repeat):

Forgotten your password?

Please enter your email address in the box below and we will contact you shortly.

Impressum

Copyright 2013
Anastrop AG

Eso-Sponge Registry | Home | Contact | English | My login data | Logout

Anastrop Tübingen 2009

select patient | new patient | Anamnesis | Treatment | Discharge | Discharge/Complications | **Status forms**

patient list | query list | statistics | data export | print

[[patient number: 000000 | registry no.: 1 | status: | current status: (select) | ...]

Status forms

	empty forms	incomplete forms	complete forms
Anamnesis			
Treatment			
Outcome			
Discharge/Complications			

Conditions of use

Until July 2016 a total of 29 patients were included by 5 different clinics in Germany. Of these patients, 25 patients had an anastomosis insufficiency and 4 patients a perforation. The mortality rate was 7 %. The treatment success rate of perforation and anastomosis insufficiency was 94 %. Numerous clinics located in Germany have expressed their interest for participation. Furthermore, the registry is planned to be expanded internationally. The Eso-SPONGE® registry is registered (NCT02662777) at www.clinicaltrials.gov. The presentation of the first data was held by Prof. Schafmayer and Dr. Heits in Berlin on the German Surgeons Congress in April 2016th. It is aimed to publish the multicentre data in a peer-reviewed journal after the inclusion of about 100 patients.

Kuehn et al.¹⁹ published their 4 years experience of endoscopic vacuum sponge therapy for esophageal anastomotic leakages. Since November 2014 the authors used Eso-SPONGE® (B. Braun, Melsungen, Germany) for E-VAC.

Between 2011-2015 in total 21 patients were treated with the E-VAC therapy. Eleven patients suffered from an esophageal anastomotic leak and 10 had a perforation. The distance of defects were 32 cm [min. 18 cm – max. 44 cm] located away from the dental arch. The leaks were diagnosed on an average of 8 days postoperatively [min. 1 – max. 18 days] whereas most of the perforation were detected within 24 h. In eleven patients the sponges were placed intraluminal and 10 patients received an intracavitary placement. The E-VAC was applied for a median duration of 15 days [min. 3 – max. 46 days] with an average number of 5 sponges insertion [min. 1 – max. 14] per patient. In total 126 sponges were inserted in 21 patients. The sponges were changed after 3 days [min. 2 – max. 4 days] and 19/21 (90.3 %) patients could be successfully treated. Success rate of anastomotic leaks was 82 % and for the perforation 100 %. Failure of the treatment was in one case a necrosis with a severe mediastinitis. Another patient died to due fulminant sepsis followed by multi-organ failure 27 days postoperatively. During a follow-up period of 17 months [min. 4 – max. 45 months] one stenosis was seen (5.0 %) which was solved by endoscopic balloon dilatation.

The authors assessed the E-VAC therapy as a promising tool to treat various defects within the upper GIT. It can be used as an isolated treatment concept or can be combined with surgical interventions. The endoscopic vacuum sponge therapy has become the first choice treatment for perforations and anastomotic leaks within the upper GIT in this center. Since November 2014 they are using the E-VAC System "Eso-SPONGE®" manufactured by B. Braun, Germany.

Smallwood et al.²⁰ described the first use of E-VAC therapy in the USA to treat upper gastrointestinal leaks or perforations.

In total six patients with perforations or leaks within the upper GIT were enrolled in this retrospective case series. In one patient the sponges were applied intraluminal and the others received an intracavitary sponge placement. The average age of the patients was 60.2 years. The E-VAC therapy was started after 12.8 days after the defect was diagnosed.

The average duration of the vacuum therapy was 35.8 days [min. 7 – max. 69 days] and the sponges were changed every 4.8 days [min. 2 – max. 9 days]. An average number of 7.2 sponge changes were performed [min. 2 – max. 12]. A complete healing of the defect was seen in all patients. Total treatment duration after the start of the therapy was 40.2 days [min. 7 – max. 69 days]. No therapy related complications were observed. None of the patients died.

The authors described the E-VAC therapy as a promising treatment option. Their publication represents the initial treatment of the first patients receiving the E-VAC therapy for perforations or leaks within the upper GIT. No prior case series has been reported in the USA so far. A successful healing of perforations and leaks were seen even in patients that failed other therapies.

A retrospective comparison of the endoscopic vacuum therapy versus stent placement for anastomotic leaks after esophagectomy regarding efficacy was conducted by **Mennigen et al.**²¹.

CLINICAL EVIDENCE

In this monocentric cohort study 45 consecutive patients were enrolled between 2009 and 2015 receiving either stent placement (N = 30) or endoscopic vacuum therapy (N = 15) for esophageal leaks treatment. After initial stent treatment 7 patients were switched to E-VAC therapy and 4 patients to surgery due to insufficient sealing of the leakage and deterioration of the patient. No treatment change was necessary in the E-VAC group. More patient in the E-VAC group obtained neoadjuvant therapy compared to the stent group (73.3 % vs. 43.3 %); $p = 0.083$. In both groups the leaks were diagnosed 7 days after surgery and the distance to the front teeth was 27–29 cm. In the E-VAC group the sponges were changed every 3–4 days. The total treatment duration was 26.5 days and 6.5 sponges were applied per patient. No treatment associated complications were reported in the E-VAC group. Median length of hospital stay was 58 days in the E-VAC group and 53 days in the stent group. Each patient in the stent group received one stent but due to stent migration and insufficient sealing of the defect up to 6 stents were needed. The median duration of stent treatment was 36 days [min. 1 – max. 560 days]. E-VAC therapy was significantly better as the stent placement because the success rate was higher in the E-VAC group compared to the stent group (93.3 % vs. 63.3 %). No difference was observed in regard to the mortality rate, length of hospital stay, and treatment duration.

In this comparative study it was demonstrated that the E-VAC is superior to stent placement for the treatment of esophageal leaks. Healing rate was significantly higher in the E-VAC therapy. This finding is in accordance with two other studies performed by Schniewind et al. and Brangewitz et al. Therefore the authors conclude that the E-VAC therapy has the potential to replace stent application as the gold standard for esophageal leaks treatment. Regarding the treatment of esophageal anastomotic leaks and perforations the method of choice is the E-VAC therapy in this center.

Möschler et al.²² performed a case series of 10 patients receiving endoscopically placed vacuum sponge therapy for anastomotic leaks and perforation within the esophagus. In 4 patients the sponge was placed intraluminal and in the remaining patients intracavitary. In most of the patients the E-VAC therapy was started later than 24 hours after diagnosis. The distance from the defect to the front teeth was between 16 and 33 cm. The length of treat-

ment duration was different depending on the placement of the sponges. For intraluminal treatment 5 days were needed whereas 14 days were reported for intracavitary vacuum therapy. In total 1–39 sponge changes were required for the healing of the defect. Closure of the defect was observed in 70 % of the patients. Patient were discharge after 14 days postoperatively. The mortality rate in this case series was 20 %. In one patient who received 39 sponge changes the therapy was stopped and a surgical rescue intervention was initiated, during this intervention the patient died. The second patient deceased due to a fulminate sepsis. In both patients the E-VAC therapy was started later than 24 h. No death occurred when the treatment was started within 24 h after diagnosis. The third patient with failed E-VAC therapy developed a large pleural emphysema leading to sepsis. Here the esophagus was removed and a colon interposition was performed.

The authors stated that the endoscopically placed sponge vacuum therapy is a valuable approach to treat esophageal leaks and should be considered by surgeons and gastroenterologists when treating these patients.

Loske et al.²³ reported a case series of 10 patients with iatrogenic perforations treated between 2007 and 2014 with the endoscopic vacuum sponge therapy. In 8 patients the sponges were placed intraluminal, one patient received an intracavitary sponge placement and in another patient the sponges were applied intracavitary as well as intraluminal. Treatment was started immediately after the perforation was diagnosed. Therapy was stopped as far as the granulation of the wound area was observed. Median location of the perforation was 31.5 cm [min. 14 – max. 40 cm] from the dental arch and a median defect size of 17.5 mm [min. 5 – max. 50 mm] was reported. In six patients the vacuum sponge treatment was terminated after the first placement of a sponge because the wound was closed after the first treatment session. Healing rate of the defect was 100 %. Median therapy duration was 5 days [min. 3 – max. 7 days] and in total 15 sponges were needed in 10 patients to care the defects. Patients were follow-up between 7 and 320 days. No complications such as stenosis occurred and no other treatment measures were needed to close the perforations. These results indicate that the E-VAC therapy will play an important role in the management of esophageal perforations.

Schorsch et al.²⁴ performed a retrospective analysis of 35 patients recruited between 2006 and 2013 suffering from an anastomosis insufficiency occurring after esophagus resection or gastrectomy (N = 21), iatrogenic perforation of the esophagus (N = 7) or other perforations (N = 7). Anastomosis insufficiencies were diagnosed after a median of 10 days (min. 3 – max. 25 days) and the perforation after 1 day (min. 0 – max. 4 days). The defect was found 15–40 cm away from the occlusal. The defect size varied from small to large. In a total of 13 patient a mediastinitis was present accompanied with a sepsis. The application of the endoscopic vacuum therapy was performed either intraluminal (N = 17) or intracavitary (N = 12), in some cases both placement option were used (N = 6). Change of the sponges were done every 4 days. A median treatment duration of 11 days including 3 sponge placements were needed to close the defect. In one patient a rupture of the sponge from the drainage hose was observed after a placement of 7 days. An ingrowth of the tissue into the sponge was not observed in any case. In total 10/21 patients were pretreated with neoadjuvant therapy. In 32 of 35 patients a healing of the defect was seen. In the leakage group, healing of the cavity was observed in 20/21 patients and in the iatrogenic perforation group healing was 100 %. A median treatment duration of 11 days was performed and the patients were examined 234 days after treatment. Ninety days survival rate was 94.3 % in this series.

The authors concluded that the E-VAC therapy is a simple, safe and minimal invasive approach for the treatment of esophageal defects of various sizes, different localizations and infection status. E-VAC is associated with a low mortality rate and leads to an excellent clinical outcome.

Bludau et al.²⁵ analysed the outcome of the E-VAC treatment retrospectively in 14 patients suffering from esophageal leaks and perforations. Patients were treated between 2010 and 2012 with the endoluminal vacuum therapy. The primary aim of this retrospective investigation was the closure rate of the leaks and the complication rate as well as the side effects of the E-VAC therapy. In 8 patients an esophageal leakage was diagnosed and in 6 patients a perforation was present. The sponge system was changed every 2–3 days. An average number of 3.9 sponges are applied and an average duration of 12.1 days were needed to

close the defect. In 6/14 patients a stent was inserted after E-VAC treatment. In 12/14 patients the E-VAC therapy was successful. Two patients died before the end of the E-VAC therapy due to a mediastinitis and consecutive sepsis (14 %). Patients were followed up for an average period of 106 days within this time frame 2 stenosis were observed which were solved by pneumatic dilation.

The authors confirmed the feasibility of E-VAC therapy for defect within the upper GIT. The combination of E-VAC treatment followed by stent placement offers a less invasive endoscopic intervention method which is a successful and leads to high closure rates.

A retrospective analysis of the clinical data regarding the E-VAC therapy performed between 2008 and 2012 for esophageal perforations was published by **Heits et al.**²⁶. In total 10 patients were included with cervical (30 %) and thoracic (70 %) esophageal perforations. In 4 patients the E-VAC therapy was started later than 24 hours. At the beginning of the therapy the sponges were changed every two days thereafter twice a week. Therapy was stopped as far as the defect reached a size of a radius of 1 cm and a depth of 2 cm. In total 54 sponges were placed in 10 patients. In most of them 1 sponge placement was conducted and the average duration of treatment was 19 ± 14.26 days. A mean number of 5.4 [min. 2 – max. 12] sponge insertion was reported. The patients were examined for 9 ± 6.4 months. A healing rate of 90 % was seen and a hospital mortality of 10 % was reported. One patient died due to a cardiovascular failure. In one patient the placement of a stent was needed after E-VAC treatment. One patient received a surgical resection after repeated Mallory-Weiss lesions. Duration of the E-VAC treatment was significantly longer ($p = 0.003$) and mortality rate was significantly higher ($p = 0.001$) for patients receiving the E-VAC therapy later than 24 hours after diagnosis of the defect.

It was concluded that the E-VAC therapy is a safe and feasible option to treat esophageal perforations. If needed E-VAC can be combined with surgical interventions and stent placement.

CLINICAL EVIDENCE

Brangewitz et al.¹⁷ aimed to compare the clinical outcome of stent placement versus E-VAC therapy for defects within the upper GIT. This retrospective case series is the first publication regarding the comparison of stent placement versus E-VAC within the mentioned indication. In total 39 patients received stent placement and 32 patients were treated with the E-VAC therapy. Before treatment 56 % of E-VAC patients and 15 % of stent patients obtained a chemotherapy or radiotherapy. Sponges were placed intraluminal as well as intracavitary. The authors found out that the E-VAC therapy was more efficient than the stent placement, because the closure rate was significantly higher in the E-VAC group (84.4 %) versus stent group (53.8 %); $p = 0.001$. Significantly more strictures were observed in the stent group (28.2 %) versus E-VAC group (9.4 %), $p < 0.05$. No significant difference was seen regarding the mortality rate (E-VAC 15 % vs. stent 25 %) and length of hospital stay (E-VAC 48.5 days vs. stent 41 days). Median duration of therapy was 23 days in E-VAC group and 33 days in the stent group. Despite the fact that more patients in the E-VAC group were pre-treated with chemotherapy or radiotherapy compared to the stent group, E-VAC was more efficient than stent placement.

In conclusion, E-VAC is a highly effective approach and showed a higher effectiveness than stent placement.

Schniewind et al.¹⁸ compared E-VAC therapy versus stent placement and surgical intervention to treat esophageal anastomotic leaks. Patients undergoing an esophagectomy between 1995 and 2012 were enrolled in this retrospective analysis. In 17 patients the E-VAC therapy was applied to care the defect, in 12 patients a stent was placed and 18 patients were surgically treated. The authors found a significantly lower mortality rate in the E-VAC group compared to other approaches. In total 2/17 died in the E-VAC group versus 9/18 in the surgically intervention group and 5/12 in the stent group. Therefore, survival rate was superior in E-VAC treated patients compared to surgically treatment ($p = 0.011$) and stent placement ($p = 0.00014$). The authors concluded that endoluminal vacuum therapy was the best treatment option for anastomotic leakages in patients after esophagectomy.

Between 2006 and 2010 in total 14 patients with an esophageal defect were treated with the E-VAC therapy by **Loske et al.**²⁷. Anastomotic leakages ($N = 8$) as well as perforations ($N = 3$) were included and the sponge was either applied intraluminal ($N = 3$) or intracavitary ($N = 10$). In one patient the sponges were placed in both positions and 3 patients were treated due to other reason (esophageal wall necrosis, spontaneous perforation, cancer perforation). Average duration of E-VAC treatment was 12 days and in average 4 sponge changes were performed per patient. Closure of the defect was achieved in 13/14 patients. One patient died due to fulminant colitis.

Authors mentioned that so far only a sample size has been treated with the innovative E-VAC therapy but the potential of this approach seems vast.

A prospective, single center study was performed by **Wedemayer et al.**¹³ to demonstrate the effectiveness E-VAC therapy for the closure of defects within the upper GIT. Esophageal leaks were observed after esophagojejunostomy ($N = 5$), esophagogastrostomy ($N = 2$), or resection of esophageal diverticula ($N = 1$). In total 6 patients have received chemotherapy or radio-chemotherapy before the E-VAC therapy was initiated. Sponges were applied for a duration of 23 ± 7.6 days and 6 sponge changes were needed to close the defect. Complete healing was seen in 7 of 8 patients. No E-VAC associated complications were observed.

Authors rated the E-VAC therapy as an effective endoscopic treatment approach for major intrathoracic leaks.

Between 2005 and 2009 **Weidenhagen et al.**¹² applied the E-VAC therapy in 6 patients with esophageal anastomotic leaks in whose all other treatment measure have failed. The defects were diagnosed between 7 and 27 days postoperatively. In average the defects were located 24 cm from the dental arch. The duration of the E-VAC last for 20 days [11-43 days]. The median number of endoscopic procedures was 10 [min. 5 – max. 16]. All sponges were

placed intracavitary. No complication related to this treatment concept was seen and no reoperation was necessary. The closure rate of the defects was 100 %. One patient died due to a pneumonia. A median length of hospital stay of 95 days [min. 63 – max. 149 days] was recorded for this case series.

These preliminary results indicate that E-VAC is a promising option to overcome the limitations associated with conventional drainage therapy.

CLINICAL EVIDENCE

Table 1: Publications using Endo-VAC to treat defects in the upper GIT.

Author	Year	Number of patients	Type of defect			Application of the sponge		
			AI N	IP N	O N	IL N	IC N	IL/IC N
Eso-SPONGE® Register Schafmayer	Status April 2016	N = 29	25	4	0	2	19	8
Kuehn et al. ¹⁹	2016	N = 21	11	10	0	11	10	0
Smallwood et al. ²⁰	2016	N = 6	1	5	0	1	5	0
Mennigen et al. ²¹	2015	N = 15	15	0	0	0	15	0
Möschler et al. ²²	2015	N = 10	10	0	0	4	6	0
Loske et al. ²³	2015	N = 10	0	0	0	8	1	1
Schorsch et al. ¹⁰	2014	N = 35	21	7	7	17	12	6
Bludau et al. ²⁵	2014	N = 14	8	4	2	NA		
Heits et al. ²⁶	2014	N = 10	0	4	6	NA		
Schorsch et al. ²⁴	2013	N = 24	17	7	0	12	8	4
Brangewitz et al. ¹⁷	2013	N = 32	30	1	1	10	22	0
Schniewind et al. ¹⁸	2013	N = 17	17	0	0	ND		
Lenzen et al. ²⁹	2013	N = 3	2	1	0	ND		
Kuehn et al. ¹⁶	2012	N = 9	5	4	0	5	2	2
Loske et al. ²⁷	2010	N = 10	5	2	3	ND		
Loske et al. ¹⁵	2010	N = 14	8	3	3	3	10	1
Wedemeyer et al. ¹³	2010	N = 8	8	0	0	ND		
Weidenhagen et al. ¹²	2010	N = 6	6	0	0	6	0	0
Ahrens et al. ¹¹	2010	N = 5	4	1	0	ND		

Legend: NA: not applied, IL: intraluminal, IC: intracavitary, AI: anastomotic insufficiency, IP: iatrogenic perforation, O: other geneses

CLINICAL EVIDENCE

CONCLUSION

Since its introduction into the market in 2015, numerous clinical investigations including over 200 patients have been performed using endoluminal vacuum therapy (E-VAC) to treat anastomotic leakages occurring after oesophageal cancer resection. The authors assessed the endoscopic endoluminal vacuum treatment as a safe and high efficient minimal invasive option. This approach is well tolerated by the patient and associated with a low complication rate. After diagnosis of the esophageal anastomotic leak the endoscopic vacuum sponge treatment should be started immediately because early treatment is more effective as late treatment regarding the clinical outcome. A longer hospital stay and a higher mortality rate has been published when the E-VAC therapy was started later than 24 hours after diagnosis of the esophageal defect. The treatment is also effective in chemo-radiotherapy pre-treated patients. In comparison to stent placement E-VAC significantly reduces the mortality rate and significantly lowers the stricture rate. Furthermore, a higher closure rate and a shorter treatment duration has been observed using E-VAC in compared to stent placement. If needed the E-VAC therapy can be combined with stent placement or with surgical intervention. A success rate between 84 % and 100 % (mean 90 %) has been reported in the literature for this minimal invasive approach after esophageal anastomotic leaks and esophageal perforation treatment. In various hospitals the E-VAC therapy has been become the first method of choice for defects occurring within the upper GIT.

KEY MESSAGES

- E-VAC treatment is a feasible, safe and high efficient approach to treat anastomotic leaks and perforations within the upper GIT^{11,13,16,19,25-29}.
- E-VAC is well tolerated and associated with good short and long term clinical outcomes^{11,25,28,29}.
- E-VAC is superior to stent placement to treat esophageal leaks; because higher closure rate, lower mortality rate, shorter treatment duration and lower stricture rate have been reported¹⁷.
- Significantly more strictures after stent insertion than after E-VAC treatment (28.2 % vs. 9.4 %, $p < 0.05$),¹⁷.
- Closure rate of leakages is significantly higher in patients treated with E-VAC compared to patient receiving a stent placement (84.4 % vs. 53.8 %),¹⁷.
- Mortality rate is significantly lower after E-VAC therapy (12 %) compared to surgical intervention (50 %, $p = 0.01$) or stent placement (83 %, $p = 0.0014$),^{17,18}.
- E-VAC treatment is associated with a low complication rate^{22,29}.
- E-VAC success rate ranges from 84 % to 100 % in the literature with a mean of 90 %²⁹.
- The earlier the E-VAC treatment is initiated after perforation and leak diagnosis the better the outcome and the lower the complication rate^{22,26,31}.
- Hospital stay is significantly longer and mortality rate is significantly higher if the E-VAC is started later than 24 hours after defect diagnosis²⁶.
- If necessary E-VAC can be combined with stent placement or operative revision for better control of the septic focus^{16,19}.
- E-VAC is used in various clinics as the first method of choice for esophageal leaks or perforations and has the potential to become the new standard of care for this indication^{18,19,21,29,31}.

J Gastrointest Surg. 2016 Feb;20(2):237–43.

Surgical Endoscopic Vacuum Therapy for Defects of the Upper Gastrointestinal Tract.

Kuehn F¹, Schiffmann L^{2,3}, Janisch F², Schwandner F², Alsfasser G², Gock M², Klar E².

Author information:

- 1 Department of General, Thoracic, Vascular and Transplantation Surgery, University of Rostock, Schillingallee 35, 18057, Rostock, Germany. florian.kuehn@med.uni-rostock.de.
- 2 Department of General, Thoracic, Vascular and Transplantation Surgery, University of Rostock, Schillingallee 35, 18057, Rostock, Germany.
- 3 Protestant Hospital Lippstadt, Wiedenbrücker Str. 33, 59555, Lippstadt, Germany.

INTRODUCTION: Intraluminal therapy used in the gastrointestinal (GI) tract was first shown for anastomotic leaks after rectal resection. Since a few years vacuum sponge therapy is increasingly being recognized as a new promising method for repairing upper GI defects of different etiology. The principles of vacuum-assisted closure (VAC) therapy remain the same no matter of localization: Continuous or intermittent suction and drainage decrease bacterial contamination, secretion, and local edema. At the same time, perfusion and granulation is promoted. However, data for endoscopic vacuum therapy (EVT) of the upper intestinal tract are still scarce and consist of only a few case reports and small series with low number of patients.

OBJECTIVES: Here, we present a single center experience of EVT for substantial wall defects in the upper GI tract.

METHODS: Retrospective single-center analysis of EVT for various defects of the upper GI tract over a time period of 4 years (2011–2015) with a mean follow-up of 17 (2–45) months was used. If necessary, initial endoscopic sponge placement was performed in combination with open surgical revision.

RESULTS: In total, 126 polyurethane sponges were placed in upper gastrointestinal defects of 21 patients with a median age of 72 years (range, 49–80). Most frequent indication for EVT was anastomotic leakage after esophageal or gastric resection (N = 11) and iatrogenic esophageal perforation (N = 8). The median number of sponge insertions was five (range, 1–14) with a mean changing interval of 3 days (range, 2–4). Median time of therapy was 15 days

(range, 3-46). EVT in combination with surgery took place in nine of 21 patients (43 %). A successful vacuum therapy for upper intestinal defects with local control of the septic focus was achieved in 19 of 21 patients (90.5 %).

CONCLUSION: EVT is a promising approach for postoperative, iatrogenic, or spontaneous lesions of the upper GI tract. In this series, EVT was combined with operative revision in a relevant proportion of patients.

Surg Endosc. 2016 Jun;**30(6):2473-80.**

The use of endoluminal vacuum (E-Vac) therapy in the management of upper gastrointestinal leaks and perforations.

Smallwood NR¹, Fleshman JW², Leeds SG³, Burdick JS⁴.

Author information:

- 1 Department of Minimally Invasive Surgery, Baylor University Medical Center at Dallas, 3500 Gaston Avenue, 1st Floor, Roberts Hospital, Dallas, TX, 75246, USA.
Nathan.smallwood@baylorhealth.edu.
- 2 Department of Surgery, Baylor University Medical Center at Dallas, 3500 Gaston Avenue, 1st Floor, Roberts Hospital, Dallas, TX, 75246, USA.
- 3 Department of Minimally Invasive Surgery, Baylor University Medical Center at Dallas, 3500 Gaston Avenue, 1st Floor, Roberts Hospital, Dallas, TX, 75246, USA.
- 4 Department of Gastroenterology, Baylor University Medical Center at Dallas, 3500 Gaston Ave, Wadley Tower Suite 556, Dallas, TX, 75246, USA.

INTRODUCTION: Upper intestinal leaks and perforations are associated with high morbidity and mortality rates. Despite the growing experience using endoscopically placed stents, the treatment of these leaks and perforations remain a challenge. Endoluminal vacuum (E-Vac) therapy is a novel treatment that has been successfully used in Germany to treat upper gastrointestinal leaks and perforations. There currently are no reports on its use in the USA.

METHODS: E-Vac therapy was used to treat 11 patients with upper gastrointestinal leaks and perforations from September 2013 to September 2014. Five patients with leaks following sleeve gastrectomy were excluded from this study. A total of six patients were treated with E-Vac therapy; these included: (N = 2) iatrogenic esophageal perforations, (N = 1) iatrogenic esophageal and gastric perforations, (N = 1) iatrogenic gastric perforation, (N = 1) gastric staple line leak following a surgical repair of a traumatic gastric perforation, and (N = 1) esophageal perforation due to an invasive fungal infection. Four patients had failed an initial surgical repair prior to starting E-Vac therapy.

ABSTRACTS

RESULTS: All six patients (100 %) had complete closure of their perforation or leak after an average of 35.8 days of E-Vac therapy requiring 7.2 different E-Vac changes. No deaths occurred in the 30 days following E-Vac therapy. One patient died following complete closure of his perforation and transfer to an acute care facility due to an unrelated complication. There were no complications directly related to the use of E-Vac therapy. Only one patient had any symptoms of dysphagia. This patient had severe dysphagia from an esophagogastric anastomotic stricture prior to her iatrogenic perforations. Following E-Vac therapy, her dysphagia had actually improved and she could now tolerate a soft diet.

CONCLUSIONS: E-Vac therapy is a promising new method in the treatment of upper gastrointestinal leaks and perforations. Current successes need to be validated through future prospective controlled studies.

J Gastrointest Surg. 2015 Jul;19(7):1229-35.

Comparison of Endoscopic Vacuum Therapy Versus Stent for Anastomotic Leak After Esophagectomy.

Mennigen R¹, Harting C, Lindner K, Vowinkel T, Rijcken E, Palmes D, Senninger N, Laukoetter MG.

Author information:

1 Department of General and Visceral Surgery, University Hospital Muenster, Albert-Schweitzer-Campus 1, Geb. W1, D-48149, Muenster, Germany, rudolf.mennigen@ukmuenster.de.

BACKGROUND: Endoscopic vacuum therapy is a novel option for the management of esophageal leaks. This study compares endoscopic vacuum therapy versus placement of covered stents for anastomotic leaks after esophagectomy.

METHODS: N = 45 consecutive patients with anastomotic leaks following esophagectomy (including patients referred to our center from other hospitals for complication management) were managed by endoscopic therapy at our institution from January 2009 to February 2015. Outcomes of stent and endoscopic vacuum therapy were analyzed retrospectively.

RESULTS: Thirty patients received endoscopic stent placement and 15 endoscopic vacuum therapy. In the stent group, seven patients were switched to endoscopic vacuum and four to surgery. Classified by type of initial endoscopic therapy, the success rate (anastomotic healing, patient recovered) was higher for endoscopic vacuum therapy (endoscopic vacuum 93.3 %, stent 63.3 %; $p = 0.038$). Classified by final endoscopic therapy (after switches in therapy), success rates were 86.4 and 60.9 % ($p = 0.091$), respectively. There was no difference observed in mortality, duration of therapy, and length of hospital stay between the study groups.

CONCLUSIONS: Endoscopic vacuum therapy might be more effective than endoscopic stent placement in the management of esophageal anastomotic leaks.

Endosc Int Open. 2015 Dec;3(6):E554-8.

Endoscopic vacuum therapy for esophageal perforations and leakages.

Möschler O¹, Nies C², Mueller MK¹.

Author information:

- 1 Department of Internal Medicine/Gastroenterology, Marienhospital Osnabrück, Osnabrück, Germany.
- 2 Department of Surgery, Marienhospital Osnabrück, Osnabrück, Germany.

BACKGROUND AND STUDY AIMS: Injuries to the esophageal wall, such as perforations and anastomotic leaks, are serious complications of surgical and endoscopic interventions. Since 2006, a new treatment has been introduced, in the form of endoscopically placed vacuum sponge therapy.

PATIENTS AND METHODS: Between April 2012 and October 2014, 10 patients (5 men and 5 women) aged 57 to 94 years were treated at our institution using endoscopic vacuum therapy (EVT) in the upper gastrointestinal tract.

RESULTS: The defect in the esophageal wall was successfully closed in seven of the 10 patients (70 %). No severe complications occurred.

CONCLUSIONS: EVT is a valuable tool for management of defects in the esophageal wall and should be considered as a treatment option for patients with this condition.

Endosc Int Open. 2015 Dec;3(6):E547-51.

Iatrogenic perforation of esophagus successfully treated with Endoscopic Vacuum Therapy (EVT).

Loske G¹, Schorsch T¹, Dahm C¹, Martens E², Müller C¹.

Author information:

- 1 Department for General, Abdominal, Thoracic and Vascular Surgery, Katholisches Marienkrankenhaus Hamburg gGmbH.
- 2 Department for Medical Oncology and Haematology, Gastroenterology and Infectious Diseases, Katholisches Marienkrankenhaus Hamburg gGmbH.

BACKGROUND AND STUDY AIMS: Endoscopic Vacuum Therapy (EVT) has been reported as a novel treatment option for esophageal leakage. We present our results in the treatment of iatrogenic perforation with EVT in a case series of 10 patients.

PATIENTS AND METHODS: An open pore polyurethane drainage was placed either intracavitary through the perforation defect or intraluminal covering the defect zone. Application of vacuum suction with an electronic device (continuous negative pressure, -125 mmHg) resulted in defect closure and internal drainage.

RESULTS: Esophageal perforations were located from the cricopharyngeus (4/10) to the esophagogastric junction (2/10). EVT was feasible in all patients. Eight patients were treated with intraluminal EVT, one with intracavitary EVT, and one with both types of treatments. All perforations (100 %) were healed in within a median of (3-7) days. No stenosis occurred, no complications were observed, and no additional operative treatment was necessary.

CONCLUSIONS: Our study suggests that intraluminal EVT will play an important role in endoscopic management of esophageal perforation.

ABSTRACTS

Surg Endosc. 2013 Jun;27(6):2040–5.

Endoscopic vacuum therapy of anastomotic leakage and iatrogenic perforation in the esophagus.

Schorsch T¹, Müller C, Loske G.

Author information:

1 Department for General, Abdominal, Thoracic, and Vascular Surgery, Katholisches Marienkrankenhaus Hamburg gGmbH, Alfredstrasse 9, 22087, Hamburg, Germany.

BACKGROUND: The management of anastomotic leakage and iatrogenic esophageal perforation has shifted over recent decades from aggressive surgery to conservative and, recently, endoscopic therapy alternatives. The authors present their results for endoscopic vacuum therapy used to treat both entities.

METHODS: In the authors' institution, 17 cases of anastomotic leakage and 7 cases of iatrogenic perforation due to interventional endoscopy or rigid panendoscopy with either intraluminal or intracavitary endoscopic vacuum therapy were treated.

RESULTS: In 23 of 24 cases, the endoscopic treatment was successful. The median duration of therapy was 11 days (range, 4–46 days). All 7 cases of iatrogenic perforation and 16 of 17 anastomotic leakage cases were cured after a median therapy duration of 5 and 12 days, respectively.

CONCLUSIONS: Endoscopic vacuum therapy is applicable for a wide range of esophageal defects. In the authors' experience, it has seemed to be the best choice for iatrogenic perforations and has been a potent supplement in the management of anastomotic leakages.

Surg Endosc. 2014 Mar;28(3):896–901.

Management of upper intestinal leaks using an endoscopic vacuum-assisted closure system (E-VAC).

Bludau M¹, Hölscher AH, Herbold T, Leers JM, Gutschow C, Fuchs H, Schröder W.

Author information:

1 Department of General, Visceral and Cancer Surgery, University of Cologne, Kerpener Strasse 62, 50937, Cologne, Germany, marc.bludau@uk-koeln.de.

BACKGROUND: Esophageal perforations and postoperative leakage of esophagogastrostomy are considered to be life-threatening conditions due to the development of mediastinitis and consecutive sepsis. Vacuum-assisted closure (VAC), a well-established treatment method for superficial infected wounds, is based on a negative pressure applied to the wound via a vacuum-sealed sponge. Endoluminal VAC (E-VAC) therapy is a novel method, and experience with its esophageal application is limited.

METHODS: This retrospective study summarizes the experience of a center with a high volume of upper gastrointestinal surgery using E-VAC therapy for patients with leakages of the esophagus. The study investigated 14 patients who had esophageal defects treated with E-VAC. Three patients had a spontaneous defect; two patients had an iatrogenic defect; and nine patients had a postoperative esophageal defect.

RESULTS: The average duration of application was 12.1 days, and an average of 3.9 E-VAC systems were used. For 6 of the 14 patients, E-VAC therapy was combined with the placement of self-expanding metal stents. Complete restoration of the esophageal defect was achieved in 12 (86 %) of the 14 patients. Two patients died due to prolonged sepsis.

CONCLUSION: This report demonstrates that E-VAC therapy adds an additional treatment option for partial esophageal wall defects. The combination of E-VAC treatment and endoscopic stenting is a successful novel procedure for achieving a high closure rate.

Ann Thorac Surg. 2014 Mar;97(3):1029–35.

Endoscopic endoluminal vacuum therapy in esophageal perforation.

Heits N¹, Stapel L¹, Reichert B¹, Schafmayer C¹, Schniewind B², Becker T¹, Hampe J³, Egberts JH⁴.

Author information:

- 1 Department of General Surgery, Visceral, Thoracic, Transplantation and Pediatric Surgery, University Hospital Schleswig-Holstein, Kiel, Germany.
- 2 Department of General Surgery, Visceral, Thoracic, Transplantation and Pediatric Surgery, University Hospital Schleswig-Holstein, Kiel, Germany; Department of General Surgery and Thoracic Surgery, Hospital of Lüneburg, Lüneburg, Germany.
- 3 Department of Internal Medicine, University Hospital TU Dresden, Dresden, Germany.
- 4 Department of General Surgery, Visceral, Thoracic, Transplantation and Pediatric Surgery, University Hospital Schleswig-Holstein, Kiel, Germany. Electronic address: jan-hendrik.egberts@uksh-kiel.de.

Comment in

Ann Thorac Surg. 2014 Mar;97(3):1035–6.

BACKGROUND: Esophageal perforation is a serious disease with a high morbidity and mortality rate. Endoscopic vacuum therapy (EVT) is a new endoscopic treatment option, which is used to treat anastomotic leakages after rectal and esophageal resections. We report on 10 patients treated with EVT for esophageal perforation.

METHODS: Clinical and therapy-related data such as age, sex, duration of intensive care stay, length of hospital stay, reasons for perforation, EVT-associated complications, mortality, need for alternative treatment options, and course of infectious variables were analyzed.

RESULTS: Ten patients were treated with 54 vacuum sponges that were placed in upper gastrointestinal defects. Causes for perforation were iatrogenic, spontaneous, or foreign body-associated. Mean number of sponge insertions was 5.4 (range, 2 to 12) with a

mean period of 19 ± 14.26 days. Successful therapy was achieved in 9 of 10 patients. After successful primary treatment, 1 patient died during therapy as a result of general failure of the cardiovascular system. In 1 patient, surgical resection was necessary after repeated Mallory-Weiss lesions and minor perforations during the course of immunosuppressive therapy. In a third patient an endoscopic stent was inserted in the clean wound cavity after primary EVT.

CONCLUSIONS: In this small trial EVT has been shown to be a safe and feasible therapy option for perforations of the upper gastrointestinal tract. If necessary, EVT can be combined with operative revision for better control of the local septic focus or used as a bridging procedure for wound conditioning before aggressive surgical treatment.

ABSTRACTS

Endoscopy. 2013 Jun;45(6):433-8.

Endoscopic closure of esophageal intrathoracic leaks: stent versus endoscopic vacuum-assisted closure, a retrospective analysis.

Brangewitz M¹, Voigtländer T, Helfritz FA, Lankisch TO, Winkler M, Klempnauer J, Manns MP, Schneider AS, Wedemeyer J.

Author information:

1 Department of Gastroenterology, Hepatology and Endocrinology, Medical School of Hannover, Hannover, Germany.

Comment in

Endoscopy. 2013 Jun;45(6):593.

BACKGROUND AND STUDY AIM: Placement of covered self-expanding metal or plastic stents (SEMS or SEPS) is an established method for managing intrathoracic leaks. Recently, endoscopic vacuum-assisted closure (EVAC) has been described as a new effective treatment option. Our aim was to compare stent placement with EVAC for nonsurgical closure of intrathoracic anastomotic leaks.

PATIENTS AND METHODS: In a retrospective analysis we were able to identify 39 patients who were treated with SEMS or SEPS and 32 patients who were treated with EVAC for intrathoracic leakage. In addition to successful fistula closure, we analyzed hospital mortality, number of endoscopic interventions, incidence of stenoses, and duration of hospitalization.

RESULTS: In a multivariate analysis, successful wound closure was independently associated with EVAC therapy (hazard ratio 2.997, 95 % confidence interval [95 % CI] 1.568 - 5.729; $p = 0.001$). The overall closure rate was significantly higher in the EVAC group (84.4 %) compared with the SEMS/SEPS group (53.8 %). No difference was found for hospitalization and hospital mortality. We found significantly more strictures in the stent group (28.2 % vs. 9.4 % with EVAC, $p < 0.05$).

CONCLUSIONS: EVAC is an effective endoscopic treatment option for intrathoracic leaks and showed higher effectiveness than stent placement in our cohort.

Surg Endosc. 2013 Oct;27(10):3883-90.

Endoscopic endoluminal vacuum therapy is superior to other regimens in managing anastomotic leakage after esophagectomy: a comparative retrospective study.

Schniewind B¹, Schafmayer C, Voehrs G, Egberts J, von Schoenfels W, Rose T, Kurdow R, Arlt A, Ellrichmann M, Jürgensen C, Schreiber S, Becker T, Hampe J.

Author information:

1 Department of General and Thoracic Surgery, University Hospital of Schleswig-Holstein, Campus Kiel, Arnold-Heller-Strasse 3 (Haus 18), 24105, Kiel, Germany, bodo.schniewind@klinikum-lueneburg.de.

BACKGROUND: Anastomotic leakage after esophagectomy is a life-threatening complication. No comparative outcome analyses for the different treatment regimens are yet available.

METHODS: In a single-center study, data from all esophagectomy patients from January 1995 to January 2012, including tumor characteristics, surgical procedure, postoperative anastomotic leakage, leakage therapy regimens, APACHE II scores, and mortality, were collected, and predictors of patient survival after anastomotic leakage were analyzed.

RESULTS: Among 366 resected patients, 62 patients (16 %) developed an anastomotic leak, 16 (26 %) of whom died. Therapy regimens included surgical revision (N = 18), endoscopic endoluminal vacuum therapy (N = 17), endoscopic stent application (N = 12), and conservative management (N = 15). APACHE II score at the initiation of treatment for leakage was the strongest predictor of in-hospital mortality ($p < 0.0017$). Conservatively managed patients showed mild systemic illness (mean APACHE II score 5) and no mortality. In systemically ill patients matched for APACHE II scores (mean, 14.4), endoscopic endoluminal vacuum therapy patients had lower mortality (12 %) compared to surgically treated (50 %, $p = 0.01$) cases and patients managed by stent placement (83 %, $p = 0.0014$, log rank test). No other clinical or laboratory parameters significantly influenced patient survival.

CONCLUSIONS: Endoscopic endoluminal vacuum therapy was the best treatment of anastomotic leakage in systemically ill patients after esophagectomy in this retrospective analysis. It should therefore be considered an important instrument in the management of this disorder.

Surg Endosc. 2010 Oct;24(10):2531–5.

Endoscopic vacuum sponge therapy for esophageal defects.

Loske G¹, Schorsch T, Müller C.

Author information:

1 Department for General, Abdominal, Thoracic and Vascular Surgery, Katholisches Marienkrankenhaus Hamburg gGmbH, Alfredstrasse 9, 22087, Hamburg, Germany.
loske.chir@marienkrankenhaus.org

BACKGROUND: Anastomotic insufficiency in esophageal anastomosis and esophageal defects of other etiology are very severe complications. For anastomotic insufficiency in the rectum, endoscopic vacuum therapy has already been used successfully. The authors used vacuum therapy for anastomotic defects and other lesions of the esophagus.

METHODS: Between November 2006 and September 2009, 10 patients (5 men and 5 women, ages 46–82 years) were treated with endoscopic vacuum sponge therapy for anastomotic insufficiency secondary to esophagectomy or gastrectomy (N = 5), iatrogenic esophageal perforation (N = 2), esophageal wall necrosis (N = 1), Boerhaave's syndrome (N = 1), and perforation of esophageal cancer (N = 1).

RESULTS: After one to seven changes of the sponge at intervals of 2–7 days and a mean therapy duration of 12 days, the defects were healed in all the surviving patients. During treatment, the patients were fed via an intestinal tube or percutaneous endoscopic gastrostomy (PEG), or enterally past the sponge. One patient died of intercurrent severe colitis. In three cases, a revision laparotomy was necessary at the beginning of treatment. No postinterventional stricture or functional relevant scar formation was observed during a follow-up period of 10–380 days after termination of the vacuum therapy.

CONCLUSION: Esophageal anastomotic insufficiency and esophageal wall defects of other causes can be treated successfully with endoscopic vacuum sponge therapy.

ABSTRACTS

Gastrointest Endosc. 2010 Feb;71(2):382–6.

Management of major postsurgical gastroesophageal intrathoracic leaks with an endoscopic vacuum-assisted closure system.

Wedemeyer J¹, Brangewitz M, Kubicka S, Jackobs S, Winkler M, Neipp M, Klemptner J, Manns MP, Schneider AS.

Author information:

1 Department of Gastroenterology, Medical School of Hannover, Hannover, Germany.

Comment in

Gastrointest Endosc. 2010 Feb;71(2):387–9.

BACKGROUND: Endoscopic treatment options for postsurgical intrathoracic leaks include injection of fibrin glue, clip application, and stent placement. Endoscopic vacuum-assisted closure (E-VAC) may be an effective treatment option.

OBJECTIVE: To demonstrate that E-VAC is an effective endoscopic treatment option for closure of major intrathoracic postsurgical leaks.

DESIGN AND SETTING: A prospective, single-center study at an academic medical center.

PATIENTS: Eight consecutive patients with major intrathoracic postsurgical leaks.

INTERVENTIONS: Endoscopic placement of transnasal draining tubes, armed with a size-adjusted sponge at their distal end, in the necrotic anastomotic cavities, followed by continuous suction. Sponge and drainage were changed twice weekly. Patients were followed-up for 193 +/- 137 days.

MAIN OUTCOME MEASUREMENT: Successful leak closure.

RESULTS: Successful closure of leaks was achieved in 7 of 8 patients (88 %) after a mean of 23 +/- 8 days. A median of 7 endoscopic interventions was necessary. No major treatment-associated short-term or long-term (follow-up, 193 +/- 137 days) complications were noted.

LIMITATIONS: Small sample size, single-center study, and lack of randomization.

CONCLUSION: E-VAC is an effective endoscopic treatment modality for major postsurgical intrathoracic leaks. (This study is registered at [Clinicaltrials.gov](https://clinicaltrials.gov), identifier NCT00876551.).

Ann Thorac Surg. 2010 Nov;90(5):1674–81.

Anastomotic leakage after esophageal resection: new treatment options by endoluminal vacuum therapy.

Weidenhagen R¹, Hartl WH, Gruetzner KU, Eichhorn ME, Spelsberg F, Jauch KW.

Author information:

1 Department of Surgery, University Hospital Campus Grosshadern, Ludwig-Maximilian-University of Munich, Munich, Germany. rolf.weidenhagen@med.uni-muenchen.de

Comment in

Ann Thorac Surg. 2010 Nov;90(5):1681.

BACKGROUND: Anastomotic leakage after esophagectomy is an important determinant of early and late morbidity and mortality. Control of the septic focus is essential when treating patients with anastomotic leakages. Surgical and endoscopic treatment options are limited.

METHODS: Between 2005 and 2009, we treated 6 patients who experienced an intrathoracic anastomotic leakage after esophageal resection. After all established therapeutic measures had failed, we explored the feasibility of an endoscopically assisted mediastinal vacuum therapy.

RESULTS: We were able to heal intrathoracic esophageal leakages in all 6 patients without any local complications and without the need for reoperation. One patient died because of a progressive pneumonia.

CONCLUSIONS: Endoscopic vacuum-assisted closure of anastomotic leakages may help to overcome the limitations that are associated with intermittent endoscopic treatment and conventional drainage therapy. Our preliminary results suggest that this new concept may be suitable for those patients.

Chirurg. 2014 Dec;85(12):1081–93.

Endoscopic vacuum therapy of perforations and anastomotic insufficiency of the esophagus.

Schorsch T¹, Müller C, Loske G.

Author information:

1 Klinik für Allgemein-, Viszeral-, Thorax-, und Gefäßchirurgie, Katholisches Marienkrankenhaus, GmbH, Alfredstr. 9, 22087, Hamburg, Deutschland.

BACKGROUND: The high morbidity and mortality of esophageal defects show that the clinical challenge in the treatment of this disease still remains. An innovative method which has been developed in recent years for esophageal leakage is endoscopic vacuum therapy.

OBJECTIVES: A retrospective analysis of all patients treated for esophageal perforation with endoscopic vacuum therapy in our department was carried out.

METHODS: From November 2006 to October 2013 a total of 35 patients were treated with this method and of these 21 had anastomotic leakage, 7 had iatrogenic perforation due to flexible or rigid endoscopy and 7 patients had esophageal defects of various other origins. Drainage systems with an open pore polyurethane tip were placed using a standard endoscope. The vacuum drainage may be positioned either in the esophageal lumen onto the defect or through the defect into the extraluminal wound cavity. The intraluminal or intracavitary vacuum drainage is connected to an electronically controlled vacuum device and a continuous negative pressure of 125 mmHg is maintained for several days. The esophageal lumen or wound cavity collapses around the drainage resulting in intraluminal evacuation and closure of the defect. Under endoscopic monitoring the vacuum system is changed regularly until stable secondary healing of the intracorporeal wound or closure of the transmural defect is achieved.

ABSTRACTS

RESULTS: In 32 out of 35 patients (91.4 %) healing of defects was achieved after median treatment duration of 11 days (range 4–78 days). The postoperative anastomotic leakage healed in 20 out of 21 patients (95.2 %) after a median of 11 days (range 4–46 days) of therapy. The defects in the 7 patients who were treated for iatrogenic perforation all healed (100 %) after a median treatment time of 5 days (range 4–7 days). There was one case of a recurrent fistula 75 days after treatment. The 90-day mortality in this series of 35 patients was 5.7 %.

DISCUSSION: The results of this retrospective study emphasize the increasing importance of endoscopic vacuum therapy in the current literature as an endoscopic treatment method in the management of esophageal perforation and anastomotic leakage.

World J Gastrointest Endosc. 2013 Jul 16;5(7):340–5.

Successful treatment of cervical esophageal leakage by endoscopic-vacuum assisted closure therapy.

Lenzen H¹, Negm AA, Erichsen TJ, Manns MP, Wedemeyer J, Lankisch TO.

Author information:

1 Henrike Lenzen, Ahmed A Negm, Thomas J Erichsen, Michael P Manns, Tim O Lankisch, Department of Gastroenterology, Hepatology and Endocrinology, Hannover Medical School, 30625 Hannover, Germany.

AIM: To evaluate the efficacy and safety of endoscopic-vacuum assisted closure (E-VAC) therapy in the treatment of cervical esophageal leakage.

METHODS: Between May and November 2012, three male patients who developed post-operative cervical esophageal leakage were treated with E-VAC therapy. One patient had undergone surgical excision of a pharyngo-cervical liposarcoma with partial esophageal resection, and the other two patients had received surgical treatment for symptomatic Zenker's diverticulum. Following endoscopic verification of the leakage, a trimmed polyurethane sponge was fixed to the distal end of a nasogastric silicone tube and endoscopically positioned into the wound cavity, and with decreasing cavity size the sponge was positioned intraluminally to cover the leak. Continuous suction was applied, and the vacuum drainage system was changed twice a week.

RESULTS: The initial E-VAC placement was technically successful for all three patients, and complete closure of the esophageal leak was achieved without any procedure-related complications. In all three patients, the insufficiencies were located either above or slightly below the upper esophageal sphincter. The median duration of the E-VAC drainage was 29 d (range: 19–49 d), with a median of seven sponge exchanges (range: 5–12 sponge exchanges). In addition, the E-VAC therapy reduced inflammatory markers to within normal range for all three patients. Two of the patients were immediately

fitted with a percutaneous enteral gastric feeding tube with jejunal extension, and the third patient received parenteral feeding. All three patients showed normal swallow function and no evidence of stricture after completion of the E-VAC therapy.

CONCLUSION: E-VAC therapy for cervical esophageal leakage was well tolerated by patients. This safe and effective procedure may significantly reduce morbidity and mortality following cervical esophageal leakage.

J Gastrointest Surg. 2012 Nov;16(11):2145-50.

Surgical endoscopic vacuum therapy for anastomotic leakage and perforation of the upper gastrointestinal tract.

Kuehn F¹, Schiffmann L, Rau BM, Klar E.

Author information:

1 Department of General, Thoracic, Vascular and Transplantation Surgery, University of Rostock, Schillingallee 35, 18057 Rostock, Germany. florian.kuehn@med.uni-rostock.de

INTRODUCTION: Emergency operations for perforations and anastomotic leakage of the upper gastrointestinal tract are associated with a high overall morbidity and mortality rate. An endoscopic vacuum therapy (EVT) has been established successfully for anastomotic leakage after rectal resection but only limited data exist for EVT of the upper GI tract.

METHODS: We report on a series of nine patients treated with EVT for defects of the upper intestinal tract between March 2011 and May 2012. In four patients, initial endoscopic sponge placement was performed in combination with open surgical revision. Median follow-up was 189 (range, 51-366) days.

RESULTS: In total, 52 vacuum sponges were placed in upper GI defects of nine patients. Indication for EVT were anastomotic leakage after esophageal resection or gastrectomy (N = 5) and iatrogenic or spontaneous esophageal perforations (N = 4). The mean number of sponge insertions was six (range, 1-13) with a mean changing interval of 3.5 days (range, 2-5). A successful vacuum therapy for upper intestinal defects was achieved in eight of nine patients (89 %).

CONCLUSION: EVT is a promising approach for postoperative, iatrogenic, or spontaneous lesions of the upper GI tract. If necessary the endoscopic procedure can be combined with operative revision for better control of the local septic focus.

ABSTRACTS

Surg Endosc. 2010 Oct;24(10):2531–5.

Endoscopic vacuum sponge therapy for esophageal defects.

Loske G¹, Schorsch T, Müller C.

Author information:

1 Department for General, Abdominal, Thoracic and Vascular Surgery, Katholisches Marienkrankenhaus Hamburg gGmbH, Alfredstrasse 9, 22087, Hamburg, Germany.
loske.chir@marienkrankenhaus.org

BACKGROUND: Anastomotic insufficiency in esophageal anastomosis and esophageal defects of other etiology are very severe complications. For anastomotic insufficiency in the rectum, endoscopic vacuum therapy has already been used successfully. The authors used vacuum therapy for anastomotic defects and other lesions of the esophagus.

METHODS: Between November 2006 and September 2009, 10 patients (5 men and 5 women, ages 46–82 years) were treated with endoscopic vacuum sponge therapy for anastomotic insufficiency secondary to esophagectomy or gastrectomy (N = 5), iatrogenic esophageal perforation (N = 2), esophageal wall necrosis (N = 1), Boerhaave's syndrome (N = 1), and perforation of esophageal cancer (N = 1).

RESULTS: After one to seven changes of the sponge at intervals of 2–7 days and a mean therapy duration of 12 days, the defects were healed in all the surviving patients. During treatment, the patients were fed via an intestinal tube or percutaneous endoscopic gastrostomy (PEG), or enterally past the sponge. One patient died of intercurrent severe colitis. In three cases, a revision laparotomy was necessary at the beginning of treatment. No postinterventional stricture or functional relevant scar formation was observed during a follow-up period of 10–380 days after termination of the vacuum therapy.

CONCLUSION: Esophageal anastomotic insufficiency and esophageal wall defects of other causes can be treated successfully with endoscopic vacuum sponge therapy.

Endoscopy. 2011 Jun;43(6):540–4.

Intraluminal and intracavitary vacuum therapy for esophageal leakage: a new endoscopic minimally invasive approach.

Loske G¹, Schorsch T, Müller C.

Author information:

1 Department for General, Abdominal, Thoracic, and Vascular Surgery, Katholisches Marienkrankenhaus, Hamburg, Germany.
loske.chir@marienkrankenhaus.org

Endoscopic treatment by placement of a vacuum sponge drainage system is a new option in the management of leakages in the digestive tract. We now distinguish between two treatment variants: the intracavitary and intraluminal techniques. A drainage system comprising an appropriately trimmed polyurethane foam sponge and a gastric-type tube is either placed through the esophageal defect into an extraluminal wound cavity (intracavitary method), or directly onto the defect with the sponge remaining within the esophageal lumen (intraluminal method). Continuous negative pressure of 125 mmHg is then applied, resulting in stabilizing of the sponge and continuous drainage and sealing of the defect. We report a case series of 14 patients, presenting the full range of possible esophageal defects that were successfully treated with either intracavitary or intraluminal vacuum therapy. Complete healing of the esophageal defect was achieved in 13 patients; one patient died due to fulminant pseudomembranous colitis while the esophageal defect was nearly healed.

Endoscopy. 2010 Sep;42(9):693-8.

Drainage of esophageal leakage using endoscopic vacuum therapy: a prospective pilot study.

Ahrens M¹, Schulte T, Egberts J, Schafmayer C, Hampe J, Fritscher-Ravens A, Broering DC, Schniewind B.

Author information:

1 Department of General Surgery and Thoracic Surgery, University Hospital Schleswig-Holstein, Kiel, Germany.

Comment in

Endoscopy. 2010 Sep;42(9):753-4.

BACKGROUND AND STUDY AIMS: Major leakage from an esophageal anastomosis is a life-threatening surgical complication. Endoscopically guided endoluminal vacuum therapy using polyurethane sponges is a new method for treating such leakage.

PATIENTS AND METHODS: Between June 2007 and June 2009, five patients (mean age 68 years) who developed anastomotic leakage after esophageal surgery were prospectively evaluated. After endoscopic diagnosis of a major leakage, polyurethane sponges were endoscopically positioned in the wound cavity of the anastomosis. Continuous suction was applied via drainage tubes fixed to the sponges. Initially sponges were endoscopically changed three times per week.

RESULTS: In all five patients treatment was successful. Median time to reduce levels of inflammation markers by 50 % was 10 days for white blood cell (WBC) count and 7 days for C-reactive protein (CRP). The smallest initial wound cavity size was 42 cm and the largest was 157 cm. The median duration of drainage was 28 days, with a median of 9 sponge changes and a median time to total cavity closure of 42 days. Two patients needed anastomotic dilation by Savary-Miller bougienage due to stenosis found on further follow-up. One of these patients died of acute severe hemorrhage from an aortoanastomotic fistula after the dilation procedure.

CONCLUSIONS: Endoscopically assisted vacuum therapy is a well-tolerated and effective therapeutic option for treatment of major esophageal leaks after surgery. Additional surgery was avoided in all cases. However, the occurrence of a delayed aortoesophageal fistula calls for careful further investigation of this new technique.

REFERENCES

1. Verbreitung von Krebserkrankungen in Deutschland. <http://edoc.rki.de>
2. Hölscher AH, Vallböhmer D, Brabender J. The prevention and management of perioperative complications. *Best Pract Res Clin Gastroenterol.* 2006;20(5):907-23.
3. Miller JD, Jain MK, de Gara CJ, Morgan D, Urschel JD. Effect of surgical experience on results of esophagectomy for esophageal carcinoma. *J Surg Oncol.* 1997 May;65(1):20-1.
4. Schmid A, Thybusch A, Kremer B, Henne-Bruns D. Differential effects of radical D2-lymphadenectomy and splenectomy in surgically treated gastric cancer patients. *Hepatogastroenterology.* 2000 Mar-Apr;47(32):579-85.
5. Pennathur A, Luketich JD. Resection for esophageal cancer: strategies for optimal management. *Ann Thorac Surg.* 2008 Feb;85(2):S751-6.
6. Rodella L, Laterza E, De Manzoni G, Kind R, Lombardo F, Catalano F, Ricci F, Cordiano C. Endoscopic clipping of anastomotic leakages in esophagogastric surgery. *Endoscopy.* 1998 Jun;30(5):453-6.
7. Peters JH, Craanen ME, van der Peet DL, Cuesta MA, Mulder CJ. Self-expanding metal stents for the treatment of intrathoracic esophageal anastomotic leaks following esophagectomy. *Am J Gastroenterol.* 2006 Jun;101(6):1393-5.
8. Infante M, Valente M, Andreani S, Catanese C, Dal Fante M, Pizzetti P, Giudice G, Basilico M, Spinelli P, Ravasi G. Conservative management of esophageal leaks by transluminal endoscopic drainage of the mediastinum or pleural space. *Surgery.* 1996 Jan;119(1):46-50.
9. Doniec JM, Schniewind B, Kahlke V, Kremer B, Grimm H. Therapy of anastomotic leaks by means of covered self-expanding metallic stents after esophagogastrectomy. *Endoscopy.* 2003 Aug;35(8):652-8.
10. Schorsch T, Müller C, Loske G. [Endoscopic vacuum therapy of perforations and anastomotic insufficiency of the esophagus]. *Chirurg.* 2014 Dec;85(12):1081-93.
11. Ahrens M, Schulte T, Egberts J, Schafmayer C, Hampe J, Fritscher-Ravens A, Broering DC, Schniewind B. Drainage of esophageal leakage using endoscopic vacuum therapy: a prospective pilot study. *Endoscopy.* 2010 Sep;42(9):693-8.
12. Weidenhagen R, Hartl WH, Gruetzner KU, Eichhorn ME, Spelsberg F, Jauch KW. Anastomotic leakage after esophageal resection: new treatment options by endoluminal vacuum therapy. *Ann Thorac Surg.* 2010 Nov;90(5):1674-81.

13. Wedemeyer J, Brangewitz M, Kubicka S, Jackobs S, Winkler M, Neipp M, Klempnauer J, Manns MP, Schneider AS. Management of major postsurgical gastroesophageal intrathoracic leaks with an endoscopic vacuum-assisted closure system. *Gastrointest Endosc.* 2010 Feb;71(2):382-6.
14. Loske G, Schorsch T, Müller C. Endoscopic intracavitary vacuum sponge therapy of anastomotic leakage in the proximal colon after right-sided colectomy. *Endoscopy.* 2010;42 Suppl 2:E171-2.
15. Loske G, Schorsch T, Müller C. Intraluminal and intracavitary vacuum therapy for esophageal leakage: a new endoscopic minimally invasive approach. *Endoscopy.* 2011 Jun;43(6):540-4.
16. Kuehn F, Schiffmann L, Rau BM, Klar E. Surgical endoscopic vacuum therapy for anastomotic leakage and perforation of the upper gastrointestinal tract. *J Gastrointest Surg.* 2012 Nov;16(11):2145-50.
17. Brangewitz M, Voigtländer T, Helfritz FA, Lankisch TO, Winkler M, Klempnauer J, Manns MP, Schneider AS, Wedemeyer J. Endoscopic closure of esophageal intrathoracic leaks: stent versus endoscopic vacuum-assisted closure, a retrospective analysis. *Endoscopy.* 2013 Jun;45(6):433-8.
18. Schniewind B, Schafmayer C, Voehrs G, Egberts J, von Schoenfels W, Rose T, Kurdow R, Arlt A, Ellrichmann M, Jürgensen C, Schreiber S, Becker T, Hampe J. Endoscopic endoluminal vacuum therapy is superior to other regimens in managing anastomotic leakage after esophagectomy: a comparative retrospective study. *Surg Endosc.* 2013 Oct;27(10):3883-90.
19. Kuehn F, Schiffmann L, Janisch F, Schwandner F, Alsfasser G, Gock M, Klar E. Surgical Endoscopic Vacuum Therapy for Defects of the Upper Gastrointestinal Tract. *J Gastrointest Surg.* 2016 Feb;20(2):237-43.
20. Smallwood NR, Fleshman JW, Leeds SG, Burdick JS. The use of endoluminal vacuum (E-Vac) therapy in the management of upper gastrointestinal leaks and perforations. *Surg Endosc.* 2016 Jun;30(6):2473-80.
21. Mennigen R, Harting C, Lindner K, Vowinkel T, Rijcken E, Palmes D, Senninger N, Laukoetter MG. Comparison of Endoscopic Vacuum Therapy Versus Stent for Anastomotic Leak After Esophagectomy. *J Gastrointest Surg.* 2015 Jul;19(7):1229-35.
22. Möschler O, Nies C, Mueller MK. Endoscopic vacuum therapy for esophageal perforations and leakages. *Endosc Int Open.* 2015 Dec;3(6):E554-8.

REFERENCES

23. Loske G, Schorsch T, Dahm C, Martens E, Müller C. Iatrogenic perforation of esophagus successfully treated with Endoscopic Vacuum Therapy (EVT). *Endosc Int Open*. 2015 Dec;3(6):E547-51.
24. Schorsch T, Müller C, Loske G. Endoscopic vacuum therapy of anastomotic leakage and iatrogenic perforation in the esophagus. *Surg Endosc*. 2013 Jun; 27(6):2040-5.
25. Bludau M, Hölscher AH, Herbold T, Leers JM, Gutschow C, Fuchs H, Schröder W. Management of upper intestinal leaks using an endoscopic vacuum-assisted closure system (E-VAC). *Surg Endosc*. 2014 Mar;28(3):896-901.
26. Heits N, Stapel L, Reichert B, Schafmayer C, Schniewind B, Becker T, Hampe J, Egberts JH. Endoscopic endoluminal vacuum therapy in esophageal perforation. *Ann Thorac Surg*. 2014 Mar;97(3):1029-35.
27. Loske G, Schorsch T, Müller C. Endoscopic vacuum sponge therapy for esophageal defects. *Surg Endosc*. 2010 Oct;24(10):2531-5.
28. Lenzen H, Negm AA, Erichsen TJ, Manns MP, Wedemeyer J, Lankisch TO. Successful treatment of cervical esophageal leakage by endoscopic-vacuum assisted closure therapy. *World J Gastrointest Endosc*. 2013 Jul 16;5(7):340-5.
29. Mennigen R, Senninger N, Laukoetter MG. Novel treatment options for perforations of the upper gastrointestinal tract: endoscopic vacuum therapy and over-the-scope clips. *World J Gastroenterol*. 2014 Jun 28;20(24):7767-76.
30. Leeds SG, Burdick JS, Fleshman JW. Endoluminal Vacuum Therapy for Esophageal and Upper Intestinal Anastomotic Leaks. *JAMA Surg*. 2016 Jun 1; 151(6):573-4.
31. Schröder W, Leers JM, Bludau M, Herbold T, Hölscher AH. Perforations near the cardia in benign diseases. *Chirurg*. 2014 Dec;85(12):1064-72.

AESCULAP® – a B. Braun brand

Aesculap AG | Am Aesculap-Platz | 78532 Tuttlingen | Germany
Phone +49 7461 95-0 | Fax +49 7461 95-2600 | www.aesculap.com

The main product trademark "Aesculap" and the product trademark "Eso-SPONGE" are registered trademarks of Aesculap AG.

Subject to technical changes. All rights reserved. This brochure may only be used for the exclusive purpose of obtaining information about our products. Reproduction in any form partial or otherwise is not permitted.